Canon
CANON MEDICAL

Shear Wave Liver 1

Performance and cutoffs for liver fibrosis staging of a two-dimensional shear wave elastography technique

The results of this study show that this 2D-shear wave elastography technique is accurate for staging liver fibrosis.

Cutoff values:

- **7 kPa significant fibrosis F2**
- **9 kPa Severe Fibrosis F3-F4**

Original article

Performance and cutoffs for liver fibrosis staging of a two-dimensional shear wave elastography technique

Giovanna Ferraioli,[a,b] Laura Maiocchi,[b] Carolina Dellafiore,[a,b] Carmine Tinelli,[c] Elisabetta Above[b] and Carlo Filice[a,b]

Objectives: To assess performance and cutoffs of the 2-dimensional shear wave elastography technique available on the Aplio i800 ultrasound system (Canon Medical Systems, Japan), using transient elastography as reference standard, and to assess the correlation of shear-wave-speed dispersion with liver fibrosis or steatosis.
Methods: This was a single-center cross-sectional study. The correlations between values obtained with transient elastography and 2-dimensional-shear wave elastography, and between shear-wave-speed dispersion and fibrosis or steatosis, were assessed with Pearson's *r*. The diagnostic performance of the 2-dimensional-shear wave elastography for staging significant fibrosis and severe fibrosis compared to transient elastography was assessed using the area under the receiver operating characteristic curve analysis.
Results: Three hundred sixty-seven patients (198 males and 169 females) were studied. There was a high correlation between 2-dimensional-shear wave elastography and transient elastography ($r = 0.87$, $P < 0.0001$). The area under the receiver operating characteristics of 2-dimensional-shear wave elastography for staging significant fibrosis (F2) and severe fibrosis (F3–F4), respectively, were 0.97 (95% confidence interval, 0.91–0.98) and 0.97 (95% confidence interval, 0.95–0.99). The best cutoffs for significant fibrosis and severe fibrosis, respectively, were > 7 and > 9 kPa. Shear-wave-speed dispersion showed a high correlation with fibrosis ($r = 0.85$, $P < 0.0001$), whereas there was a very weak correlation with steatosis.
Conclusions: The results of this study show that this 2-dimensional-shear wave elastography technique is accurate for staging liver fibrosis. Shear-wave-speed dispersion is highly correlated with liver fibrosis but not with steatosis. Eur J Gastroenterol Hepatol XXX: 00–00

Introduction

Liver fibrosis, which is due to the healing process of necroinflammation, is a common feature of chronic liver disease; it may lead to cirrhosis with its complications. For the treatment and prognosis of patients with chronic liver disease, it is important to assess whether the patient has significant fibrosis (F2 stage) or liver cirrhosis (F4 stage) [1]. On the other hand, the spectrum of fibrosis is a continuum; therefore, the term 'compensated advanced chronic liver disease,' which includes severe fibrosis (F3) and liver cirrhosis (F4) at an early [2]. In fact, esophageal varices can occur not only in patients with established cirrhosis but also in patients with severe fibrosis [2,3].

Nowadays, guidelines have accepted that liver stiffness assessment with shear wave elastography (SWE) can replace liver biopsy in several clinical scenarios [4].

Indeed, several studies and meta-analyses have shown that the SWE techniques are accurate for the evaluation of liver fibrosis. The first SWE technique available on the market was transient elastography (TE), which is performed with a dedicated device. It has become a point-

Journal Info	European Journal of Gastroenterology & Hepatology Feb 2020 https://doi.org/10.1097/MEG.0000000000001702
Year	**2020**
Authors	G. Ferraioli, L. Maiocchi, C. Dellafiore, C. Tinelli, C. Filice (Italy)
System used	Aplio i800

Back

Canon
CANON MEDICAL

Shear Wave Liver 2

Liver stiffness assessed with the help of the propagation map of a latest software for 2D shear wave elastography: Preliminary results

Propagation map of the latest software for 2D shear wave elastography implemented in the Aplio 500 system is a useful tool for the assessment of liver stiffness because it helps in choosing the area of liver parenchyma where measurements are likely more reliable.

EPOS™
Electronic Presentation Online System

ESR
European Society of Radiology

Liver stiffness assessed with the help of the propagation map of a latest software for 2D shear wave elastography: preliminary results

Poster No.:	C-0754
Congress:	ECR 2016
Type:	Scientific Exhibit
Authors:	G. Ferraioli, L. Maiocchi, R. Lissandrin, C. Tinelli, C. Filice; Pavia/IT
Keywords:	Cirrhosis, Diagnostic procedure, Ultrasound, Elastography, Liver
DOI:	10.1594/ecr2016/C-0754

Journal Info	ECR 2016 Poster C-0754 http://dx.doi.org/10.1594/ecr2016/C-0754
Year	**2016**
Authors	G. Ferraioli, L. Maiocchi, R. Lissandrin, C. Tinelli, C. Filice (Italy)
System used	Aplio

Back

Canon
CANON MEDICAL

Shear Wave Liver 3

Accuracy of the lastest release of a 2D Shear Wave elastography method for staging liver fibrosis in patients with chronic hepatitis C: Preliminary results

The optimal cutoff values of the 2D shear wave elastography method:

- F≥2: 6.6 kPa
- F≥3 9.4 kPa
- F=4 11.2 kPa.

F-45

ACCURACY OF THE LATEST RELEASE OF A 2D SHEAR WAVE ELASTOGRAPHY METHOD FOR STAGING LIVER FIBROSIS IN PATIENTS WITH CHRONIC HEPATITIS C: PRELIMINARY RESULTS

G. Ferraioli [1], L. Maiocchi [1], R. Lissandrin [1], C. Tinelli [2], C. Filice [1]
[1] Ultrasound Unit, Infectious Diseases Department, Fondazione IRCCS Policlinico S. Matteo, Medical School University of Pavia, Pavia, Italy
[2] Clinical Epidemiology and Biometric Unit, Fondazione IRCCS Policlinico S. Matteo, Pavia, Italy

Aim: This single center cross-sectional study was conducted to prospectively assess the performance of the latest release of a 2D shear wave elastography method by comparing the results to those obtained with transient elastography (TE).

Materials and methods: Consecutive patients followed up for chronic hepatitis C and referred for abdominal ultrasound examination were enrolled. Liver stiffness measurements were performed with the latest release of a 2D shear wave elastography method implemented in the Aplio 500 ultrasound system (Toshiba Medical Systems, Japan) and with the TE method of the FibroScan® device (Echosens, France). The two systems were used in a random order. For staging liver fibrosis we used the TE cutoffs of 7.0, 9.5 and 12.0 kPa, respectively, for significant fibrosis (F≥2), advanced fibrosis (F≥3), and cirrhosis (F=4). The diagnostic performance of the 2D shear wave elastography method was assessed by calculating the area under the receiver operating characteristic (AUC) curve.

Results: 73 patients [48 males, 25 females; mean age, 58.3 (12.0) years] were studied. 25 individuals were in F0–F1 stage, 12 in F2 stage, 8 in F3 stage, and 28 in F4 stage. The optimal cutoff values of the 2D shear wave elastography method for F≥2, F≥3, F=4, respectively, were 6.6, 9.4 and 11.2 kPa. AUC calculations showed values of 0.99 (0.92–1.00) for F≥2 [sensitivity, 100% (91.6–100.0); specificity, 94.4% (72.7–99.9); LR+, 18.0 (2.7–120.9); LR–, 0(0)]; 1.00 (0.94–1.00) for F≥3 [sensitivity, 96.9% (83.8–99.9); specificity, 100% (87.7–100.0); LR+, calculation not possible; LR–,0.03 (0.005–0.2)]; 0.98 (0.91–1.00) for F = 4 [sensitivity, 88.0% (68.8–97.5); specificity, 97.1% (85.1–99.9); LR+, 30.8 (4.4–213.7); LR–, 0.12 (0.04–0.4)].

Journal Info	Digestive and Liver Disease 48S (2016) e62 http://dx.doi.org/10.1016/j.dld.2015.12.143
Year	**2016**
Authors	G. Ferraioli, L. Maiocchi, R. Lissandrin, C. Tinelli, C. Filice (Italy)
System used	Aplio 500

Back

Canon
CANON MEDICAL

Shear Wave Liver 4

Variability of Liver Shear Wave Measurements Using a New Ultrasound Elastographic Technique

2D SWE showed low overall measurement variability, with a **minimum of 5 readings providing equivalent precision to the existing method using 10 samples**.

Journal of Ultrasound in Medicine | The multidisciplinary medical ultrasound journal | aium

Original Research

Variability of Liver Shear Wave Measurements Using a New Ultrasound Elastographic Technique

David P. Nadebaum MBBS, BMedSci, Amanda J. Nicoll MBBS, FRACP, PhD, Siddharth Sood MBBS, FRACP, PhD, Alexandra Gorelik MSc, ... See all authors

First published: 29 September 2017 | https://doi.org/10.1002/jum.14375

Toshiba Healthcare loaned the ultrasound device used for shear wave measurements. Toshiba did not have influence over study design, data collection, data analysis, or manuscript preparation. ... Less

Journal Info	Journal of Ultrasound in Medicine, vol 37 https://doi.org/10.1002/jum.14375
Year	**2017**
Authors	David P. Nadebaum, Amanda J. Nicoll, Siddharth Sood, Alexandra Gorelik, Robert N. Gibson (Australia)
System used	Aplio 500

Back

Canon
CANON MEDICAL

Shear Wave Liver 5

Concordance of transient elastography and shear wave elastography for measurement of liver stiffness

SWE obtained using the Toshiba Aplio 500 and TE provides similar measurements for liver stiffness measurements of liver diseases. SWE has good inter-operator reliability and may be advantageous over TE owing to the availability of B-mode interrogation simultaneously and the reliability indicators this technology provides.

SONOGRAPHY

ORIGINAL ARTICLE

Concordance of transient elastography and shear wave elastography for measurement of liver stiffness

Sandra O'Hara[1,2], Susan Hodson[3], Chandelle Hernaman[1], Nick Wambeek[1], John Olynyk[3,4]

1 SKG Radiology, Western Australia, Australia
2 Department of Medical Radiation Sciences, Curtin University, Western Australia, Australia
3 Department of Gastroenterology and Hepatology, Fiona Stanley and Fremantle Hospital Group, Western Australia, Australia
4 School of Medical and Health Sciences, Edith Cowan University, Western Australia, Australia

Keywords
elastography, shear wave, transient, liver, fibrosis, cirrhosis.

Correspondence
Sandra O'Hara, SKG Radiology, West Perth, Perth, Western Australia.
E-mail: sandra.ohara@skg.com.au

Received: 17 June 2017; revised 28 July 2017; accepted 28 July 2017

doi:10.1002/sono.12122

Abstract

Introduction: Transient elastography is commonly utilised in liver clinics as a non-invasive method of assessing the degree of fibrosis or presence of cirrhosis in the human liver. Many ultrasound vendors are now providing ultrasound shear wave elastography on commercial ultrasound units. There is limited published data evaluating the performance of ultrasound elastography compared to transient elastography.
Methods: This study compared the performance of ultrasound shear wave elastography, on an ultrasound unit with transient elastography in 29 participants with liver diseases of varying aetiologies.
Results: The mean shear wave pressure for transient elastography and ultrasound shear wave elastography was 7.58 kPa (SD 3.26) and 7.29 (SD 2.02), respectively, with 18 cases having a less than 30% deviation of shear wave elastography from transient elastography.
Conclusion: Both methods provide similar measurements of fibrosis and may be useful non-invasive measures of hepatic fibrosis and cirrhosis.

Journal Info	Sonography 4 141–145 © 2017 Australasian Sonographers Association https://onlinelibrary.wiley.com/doi/pdf/10.1002/sono.12122
Year	**2017**
Authors	Sandra O'Hara, Susan Hodson, Chandelle Hernaman, Nick Wambeek, John Olynyk (Australia)
System used	Aplio 500

Canon
CANON MEDICAL

ATI Liver 1

Detection of Liver Steatosis With a Novel Ultrasound-Based Technique: A Pilot Study Using MRI-Derived Proton Density Fat Fraction as the Gold Standard (2019)

Comparison of steatosis respective diagnostic performance between ATI and CAP vs MRI PDFF ("gold standard")

ATI performed better than CAP, and this improvement was statistically significant for S > 1

ATI Cutoff values for steatosis grading (dB/cm/kHz):

S0	No steatosis	**< 0,63**
S1	Mild Steatosis	**0,63 – 0,72**
S2-S3	Significant & Severe Steatosis	**> 0,72**

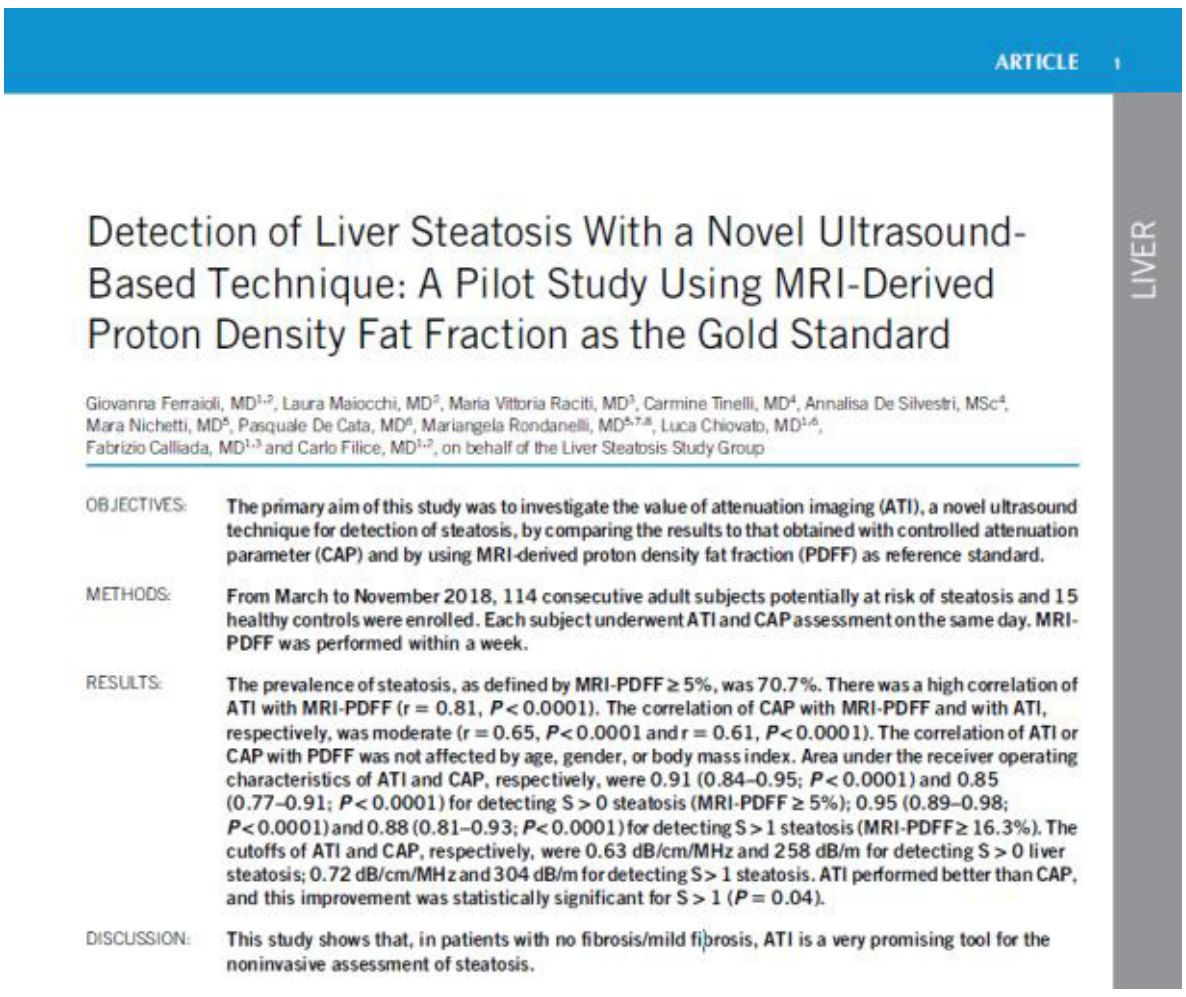
ARTICLE 1

LIVER

Detection of Liver Steatosis With a Novel Ultrasound-Based Technique: A Pilot Study Using MRI-Derived Proton Density Fat Fraction as the Gold Standard

Giovanna Ferraioli, MD[1,2], Laura Maiocchi, MD[2], Maria Vittoria Raciti, MD[3], Carmine Tinelli, MD[4], Annalisa De Silvestri, MSc[4], Mara Nichetti, MD[5], Pasquale De Cata, MD[6], Mariangela Rondanelli, MD[5,7,8], Luca Chiovato, MD[1,6], Fabrizio Calliada, MD[1,3] and Carlo Filice, MD[1,2], on behalf of the Liver Steatosis Study Group

OBJECTIVES: The primary aim of this study was to investigate the value of attenuation imaging (ATI), a novel ultrasound technique for detection of steatosis, by comparing the results to that obtained with controlled attenuation parameter (CAP) and by using MRI-derived proton density fat fraction (PDFF) as reference standard.

METHODS: From March to November 2018, 114 consecutive adult subjects potentially at risk of steatosis and 15 healthy controls were enrolled. Each subject underwent ATI and CAP assessment on the same day. MRI-PDFF was performed within a week.

RESULTS: The prevalence of steatosis, as defined by MRI-PDFF ≥ 5%, was 70.7%. There was a high correlation of ATI with MRI-PDFF (r = 0.81, $P < 0.0001$). The correlation of CAP with MRI-PDFF and with ATI, respectively, was moderate (r = 0.65, $P < 0.0001$ and r = 0.61, $P < 0.0001$). The correlation of ATI or CAP with PDFF was not affected by age, gender, or body mass index. Area under the receiver operating characteristics of ATI and CAP, respectively, were 0.91 (0.84–0.95; $P < 0.0001$) and 0.85 (0.77–0.91; $P < 0.0001$) for detecting S > 0 steatosis (MRI-PDFF ≥ 5%); 0.95 (0.89–0.98; $P < 0.0001$) and 0.88 (0.81–0.93; $P < 0.0001$) for detecting S > 1 steatosis (MRI-PDFF ≥ 16.3%). The cutoffs of ATI and CAP, respectively, were 0.63 dB/cm/MHz and 258 dB/m for detecting S > 0 liver steatosis; 0.72 dB/cm/MHz and 304 dB/m for detecting S > 1 steatosis. ATI performed better than CAP, and this improvement was statistically significant for S > 1 ($P = 0.04$).

DISCUSSION: This study shows that, in patients with no fibrosis/mild fibrosis, ATI is a very promising tool for the noninvasive assessment of steatosis.

Journal Info	Clinical and Translational Gastroenterology 2019;00:e00081 https://doi.org/10.14309/ctg.0000000000000081
Year	**2019**
Authors	G. Ferraioli, L. Maiocchi, R. Lissandrin, C. Tinelli, F. Calliada, C. Filice (Italy)
System used	Aplio i800

Back

Canon
CANON MEDICAL

ATI Liver 2

Assessment of hepatic steatosis by using attenuation imaging: A quantitative, easy-to-perform ultrasound technique

The acoustic coefficient (AC) from ATI provided good diagnostic performance in detecting the varying degrees of hepatic steatosis. The degree of steatosis was the only significant factor affecting the AC, whereas fibrosis and inflammation were not.

Cutoff values for steatosis grading (dB/cm/kHz):

S0	S1	S2	S3
No Steatosis	Mild Steatosis	Moderate Steatosis	Severe Steatosis
< 0,63	**< 0,70**	**> 0,70**	**> 0,75**

European Radiology
https://doi.org/10.1007/s00330-019-06272-y

HEPATOBILIARY-PANCREAS

Check for updates

Assessment of hepatic steatosis by using attenuation imaging: a quantitative, easy-to-perform ultrasound technique

Jae Seok Bae[1,2] · Dong Ho Lee[1,2] · Jae Young Lee[1,2,3] · Haeryoung Kim[4] · Su Jong Yu[5] · Jeong-Hoon Lee[5] · Eun Ju Cho[5] · Yun Bin Lee[5] · Joon Koo Han[1,2,3] · Byung Ihn Choi[6]

Received: 27 February 2019 / Revised: 2 May 2019 / Accepted: 10 May 2019

Abstract
Objectives To evaluate the diagnostic performance of attenuation imaging (ATI) in the detection of hepatic steatosis compared with a histopathology gold standard.
Methods We prospectively enrolled 108 consecutive patients (35 males; median age, 54.0 years) who underwent percutaneous liver biopsy for evaluation of diffuse liver disease between January 2018 and November 2018 in a tertiary academic center. Grayscale ultrasound examination with ATI was performed just before biopsy, and an attenuation coefficient (AC) was obtained from each patient. The degree of hepatic steatosis, fibrosis stage, and necroinflammatory activity were assessed on histopathologic examination. The significant factor associated with the AC was found by a linear regression analysis, and the diagnostic performance of the AC for the classification into each hepatic steatosis stage was evaluated by receiver operating characteristic (ROC) analysis.
Results The distribution of hepatic steatosis grade on histopathology was 53/11/22/16/6 for none/mild (< 10%)/mild (≥ 10%)/moderate/severe steatosis, respectively. The area under the ROC curve, sensitivity, specificity, and optimal cutoff AC value for

Journal Info	European radiology https://doi.org/10.1007/s00330-019-06272-y
Year	**2019**
Authors	Jae Seok Bae, Dong Ho Lee, Jae Young Lee, Haeryoung Kim, Su Jong Yu, Jeong-Hoon Lee, Eun Ju Cho & al
System used	Aplio i800

Back

CANON MEDICAL

ATI Liver 3

Prospective Evaluation of Hepatic Steatosis using Ultrasound Attenuation Imaging in Patients with Chronic Liver Disease with Magnetic Resonance Imaging Proton Density Fat Fraction as the Reference Standard

ATI attenuation coefficients are well correlated with MRI-PDFF and, thus, may provide good diagnostic performance in the assessment of hepatic steatosis, making these coefficients a promising tool for the non-invasive assessment and quantification of hepatic steatosis

Cutoff value for detection of steatosis

- **MRI-PDFF > 5%   0,59 dB/cm/MHz**
- **MRI-PDFF > 10%   0,65 dB/cm/MHz**

ELSEVIER

Check for updates

Ultrasound in Med. & Biol., Vol. 45, No. 6, pp. 1407–1416, 2019

0301-5629/$ - see front matter

https://doi.org/10.1016/j.ultrasmedbio.2019.02.008

● *Original Contribution*

PROSPECTIVE EVALUATION OF HEPATIC STEATOSIS USING ULTRASOUND ATTENUATION IMAGING IN PATIENTS WITH CHRONIC LIVER DISEASE WITH MAGNETIC RESONANCE IMAGING PROTON DENSITY FAT FRACTION AS THE REFERENCE STANDARD

Sun Kyung Jeon,[*] Jeong Min Lee,[*,†,‡] Ijin Joo,[*,†] Jeong Hee Yoon,[*,†] Dong Ho Lee,[*,†] Jae Young Lee,[*,†,‡] and Joon Koo Han[*,†,‡]

[*] Department of Radiology, Seoul National University Hospital, Seoul, South Korea; [†] Seoul National University College of Medicine, Seoul, South Korea; and [‡] Institute of Radiation Medicine, Seoul National University Medical Research Center, Seoul, South Korea

(*Received* 26 *October* 2018; *revised* 31 *January* 2019; *in final from* 6 *February* 2019)

Abstract—The purpose of our study was to investigate the diagnostic performance of 2-D ultrasound attenuation imaging (ATI) for the assessment of hepatic steatosis in patients with chronic liver disease using magnetic resonance imaging proton density fat fraction (MRI-PDFF) as the reference standard. We prospectively analyzed 87 patients with chronic liver disease who had reliable measurements at both ATI and MRI-PDFF. For the detection of hepatic steatosis of MRI-PDFF ≥5% and MRI-PDFF ≥10%, ATI measurements yielded areas under the

Journal Info	Ultrasound in Med. & Biol., Vol. 45, No. 6, pp. 14071416 https://doi.org/10.1016/j.ultrasmedbio.2019.02.008
Year	**2019**
Authors	Adegpst Un Kyung Jeon, Jeong Min Lee, Ijin Joo, Jeong Hee Yoon, Dong Ho Lee, Jae Young Lee, Joon Koo Han (Korea)
System used	Aplio i800

Back

CANON MEDICAL

ATI Liver 4

Quantification of hepatic steatosis with ultrasound: promising role of attenuation imaging coefficient in a biopsy-proven cohort

ATI coefficient has a significant positive correlation with the grade of steatosis and is a promising quantitative technique for the noninvasive diagnosis and quantification of hepatic steatosis.

Measurement of the attenuation coefficient is achieved with a very high rate of technical success.

Cutoff value for detection of steatosis

- **S0 vs S1-2-3** **0,69 dB/cm/MHz**
- **S0-1 vs S2-3** **0,72 dB/cm/MHz**

European Radiology
https://doi.org/10.1007/s00330-019-06480-6

GASTROINTESTINAL

Check for updates

Quantification of hepatic steatosis with ultrasound: promising role of attenuation imaging coefficient in a biopsy-proven cohort

Marco Dioguardi Burgio[1,2] · Maxime Ronot[1,2,3] · Edouard Reizine[1] · Pierre-Emmanuel Rautou[4] · Laurent Castera[4] · Valérie Paradis[5] · Philippe Garteiser[2] · Bernard Van Beers[1,2,3] · Valérie Vilgrain[1,2,3]

Received: 12 March 2019 / Revised: 30 August 2019 / Accepted: 27 September 2019

Abstract
Objectives To prospectively assess the role of the US attenuation imaging coefficient (AC) for the diagnosis and quantification of hepatic steatosis.
Methods One hundred and one patients underwent liver biopsy and US-AC measurement on the same day. Liver steatosis was graded according to biopsy as absent (S0 < 5%), mild (S1 5–33%), moderate (S2 33–66%), or severe (S3 > 66%); liver fibrosis was graded from F0 to F4. The correlation between AC and steatosis on pathology (%) was calculated using the Pearson correlation coefficient. The Student t or Mann–Whitney U test was used to compare continuous variables and ROC curve analysis was used to assess diagnostic performance of AC in diagnosing steatosis.
Results Overall, 43 (42%), 35 (35%), 12 (12%), and 11 (11%) patients were classified as S0, S1, S2, and S3, respectively. The AC was positively correlated with steatosis as a continuous variable (%) on pathology ($r = 0.58$, $p < 0.01$). Patients with steatosis of any grade had a higher AC than those without steatosis (mean 0.77 ± 0.13 vs. 0.63 ± 0.09 dB/cm/MHz, respectively; $p < 0.01$, AUROC = 0.805). Patients with S2–S3 had a higher AC than patients with S0–1 (0.85 ± 0.11 vs. 0.67 ± 0.11 dB/cm/MHz, respectively; $p < 0.01$, AUROC = 0.892). AC > 0.69 dB/cm/MHz had a sensitivity and specificity of 76% and 86%, respectively, for diagnosing any grade of steatosis (S1–S3), and AC > 0.72 dB/cm/MHz had a sensitivity and specificity of 96% and 74%, respectively, for diagnosing S2–S3. The presence of advanced fibrosis (F3–F4) did not affect the calculated AC.
Conclusions The attenuation imaging coefficient is a promising quantitative technique for the non-invasive diagnosis and quantification of hepatic steatosis.
Key Points
• *Measurement of the attenuation coefficient is achieved with a very high rate of technical success.*
• *We found a significant positive correlation between the attenuation coefficient and the grade of steatosis on pathology.*
• *The attenuation imaging coefficient is a promising quantitative technique for the noninvasive diagnosis and quantification of hepatic steatosis.*

Keywords Liver steatosis · Ultrasonography · NAFLD

Journal Info	European Radiology https://doi.org/10.1007/s00330-019-06480-6
Year	**2019**
Authors	Marco Dioguardi Burgio, Maxime Ronot, Edouard Reizine, Pierre-Emmanuel Rautou, Laurent Castera, Valérie Paradis, Philippe Garteiser, Bernard Van Beers, Valérie Vilgrain (France)
System used	Aplio i800

Back

Canon
CANON MEDICAL

SWD Liver 1

Clinical utilization of shear wave dispersion imaging in diffuse liver disease

SW dispersion slope is more useful than SW speed for predicting the degree of necro-inflammation.
Dispersion slope, which reflects viscosity, may provide additional pathophysiological insight into diffuse liver disease.

Clinical utilization of shear wave dispersion imaging in diffuse liver disease

ULTRA SONO GRAPHY

Katsutoshi Sugimoto[1], Fuminori Moriyasu[2], Hisashi Oshiro[3], Hirohito Takeuchi[1], Yu Yoshimasu[1], Yoshitaka Kasai[1], Takao Itoi[1]

[1]Department of Gastroenterology and Hepatology, Tokyo Medical University, Tokyo; [2]Department of Gastroenterology and Hepatology, International University of Health and Welfare, Sanno Hospital, Tokyo; [3]Department of Pathology, Jichi Medical University, Shimotsuke, Japan

REVIEW ARTICLE
https://doi.org/10.14366/usg.19031
pISSN: 2288-5919 • eISSN: 2288-5943
Ultrasonography. 2019 Jul 26.
Epub ahead of print

Shear wave (SW) dispersion imaging is a newly developed imaging technology for assessing the dispersion slope of SWs, which is related to tissue viscosity in diffuse liver disease. Our preclinical and preliminary clinical studies have shown that SW speed is more useful than dispersion slope for predicting the degree of fibrosis and that dispersion slope is more useful than SW speed for predicting the degree of necroinflammation. Thus, dispersion slope, which reflects viscosity, may provide additional pathophysiological insight into diffuse liver disease.

Keywords: Ultrasonography; Elasticity; Viscosity; Dispersion; Shear wave elastography; Liver

Received: May 31, 2019
Revised: July 25, 2019
Accepted: July 26, 2019

Correspondence to:
Katsutoshi Sugimoto, MD, Department of Gastroenterology and Hepatology, Tokyo Medical University, 6-7-1 Nishishinjuku, Shinjuku-ku, Tokyo 160-0023, Japan
Tel. +81-3-3342-6111
Fax. +81-3-5381-6654
E-mail: sugimoto@tokyo-med.ac.jp

Introduction

Shear wave elastography (SWE) is an emerging technology that provides information concerning tissue elasticity by emitting an acoustic radiation force impulse to generate laterally propagating shear waves (SWs), and it can also provide biochemical information concerning tissue quality [1–3]. Furthermore, viscosity also provides biochemical information concerning tissue quality, as viscosity is considered to be a different property than elasticity [4–6]. However, most ultrasound (US) elastographic models use a linear elastic model to describe tissue mechanical properties, and only tissue elasticity is quantified. It is now well known that dispersion is related to the frequency-dependence of the speed of SWs and the attenuation of SWs in the viscous component [7]. If a tissue is dispersive, the speed and attenuation of SWs increase with frequency [7]. Analysis of the dispersion properties of SWs can therefore serve as an indirect method for measuring viscosity. A new imaging technology known as shear wave dispersion imaging (SWD; Canon Medical Systems Corporation, Otawara, Japan) has recently been developed for evaluating the dispersion of SWs, which is related to the viscosity of liver tissue [8]. In this review article, the feasibility of liver viscosity evaluation using SWD is assessed based on the findings of preliminary animal experiments and clinical evaluations.

Journal Info	Ultrasonography. 2019 Jul 26 https://doi.org/10.14366/usg.19031
Year	**2019**
Authors	Katsutoshi Sugimoto, Fuminori Moriyasu, Hisashi Oshiro, Hirohito Takeuchi, Yu Yoshimasu, Yoshitaka Kasai, Takao Itoi (Japan)
System used	Aplio i800

Back

CANON MEDICAL

SWD Liver 2

Shear-Wave Dispersion Slope from US SWE: Detection of Allograft Damage after Liver Transplantation

Shear-wave dispersion slope is associated with both liver fibrosis and degree of necro-inflammatory activity (*P* , .01) after liver transplant and provided **better diagnostic performance than liver stiffness value in detection of allograft damage after liver transplant**.

Cutoff SWD (m/s/kHz)	Sensitivity	Specificity	PPV	NPV
10,8	97,8	62,1	67%	**97%**
12	80,4	67,2	66%	81%
14	56,5	86,2	**76%**	71%

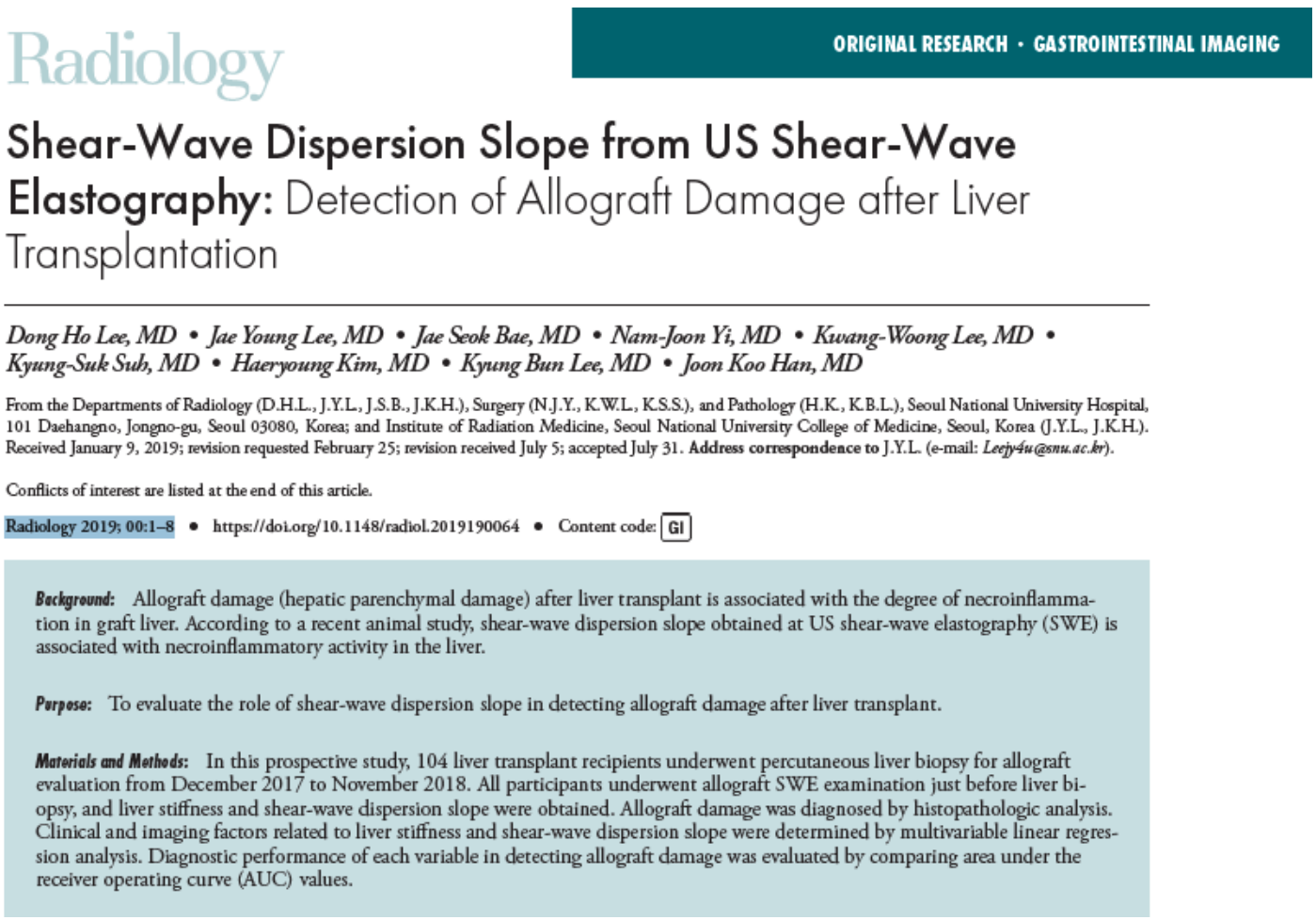
Radiology

ORIGINAL RESEARCH • GASTROINTESTINAL IMAGING

Shear-Wave Dispersion Slope from US Shear-Wave Elastography: Detection of Allograft Damage after Liver Transplantation

Dong Ho Lee, MD • Jae Young Lee, MD • Jae Seok Bae, MD • Nam-Joon Yi, MD • Kwang-Woong Lee, MD • Kyung-Suk Suh, MD • Haeryoung Kim, MD • Kyung Bun Lee, MD • Joon Koo Han, MD

From the Departments of Radiology (D.H.L., J.Y.L., J.S.B., J.K.H.), Surgery (N.J.Y., K.W.L., K.S.S.), and Pathology (H.K., K.B.L.), Seoul National University Hospital, 101 Daehangno, Jongno-gu, Seoul 03080, Korea; and Institute of Radiation Medicine, Seoul National University College of Medicine, Seoul, Korea (J.Y.L., J.K.H.).
Received January 9, 2019; revision requested February 25; revision received July 5; accepted July 31.
Address correspondence to J.Y.L. (e-mail: *Leejy4u@snu.ac.kr*).

Conflicts of interest are listed at the end of this article.

Radiology 2019; 00:1–8 • https://doi.org/10.1148/radiol.2019190064 • Content code: GI

Background: Allograft damage (hepatic parenchymal damage) after liver transplant is associated with the degree of necroinflammation in graft liver. According to a recent animal study, shear-wave dispersion slope obtained at US shear-wave elastography (SWE) is associated with necroinflammatory activity in the liver.

Purpose: To evaluate the role of shear-wave dispersion slope in detecting allograft damage after liver transplant.

Materials and Methods: In this prospective study, 104 liver transplant recipients underwent percutaneous liver biopsy for allograft evaluation from December 2017 to November 2018. All participants underwent allograft SWE examination just before liver biopsy, and liver stiffness and shear-wave dispersion slope were obtained. Allograft damage was diagnosed by histopathologic analysis. Clinical and imaging factors related to liver stiffness and shear-wave dispersion slope were determined by multivariable linear regression analysis. Diagnostic performance of each variable in detecting allograft damage was evaluated by comparing area under the receiver operating curve (AUC) values.

Journal Info	Radiology 2019; 00:1–8 https://doi.org/10.1148/radiol.2019190064
Year	**2019**
Authors	Jeong Hee Yoon, Dong Ho Lee, Jae Young Lee, Joon Koo Han (Korea)
System used	Aplio i800

Back