TOSHIBA MEDICAL SYSTEMS CORPORATION

http://www.toshibamedicalsystems.com

©Toshiba Medical Systems Corporation 2017. All rights reserved.
Design and specifications subject to change without notice.
Model number: TSX-036A MCACT0303EA 2017-03 TMSC/XX/Printed in Japan

Toshiba Medical Systems Corporation meets internationally recognized standards for Quality Management System ISO 9001, ISO 13485.
Toshiba Medical Systems Corporation Nasu Operations meets the Environmental Management System standard ISO 14001.

Aquilion Lightning, SEMAR, SURE Start and Made for Life are trademarks of Toshiba Medical Systems Corporation.

Made For life

TOSHIBA
MEDICAL

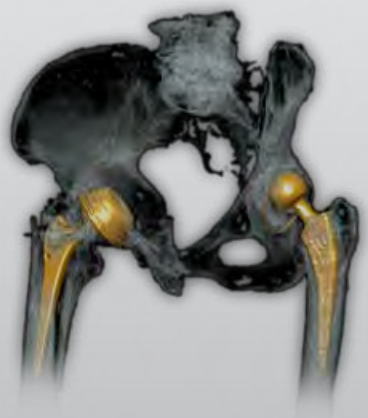

CT Clinical Image Gallery

Aquilion™ Lightning

80 Detector Row

Table of contents

Brain — 4

Brain with Contrast — 5

Brain and Cervical Spine — 6

Neck with Contrast — 7

Chest — 8

Chest Post Contrast — 9

Chest Pulmonary Angiogram — 10

Chest, Abdomen and Pelvis — 12

Abdomen — 14

Pelvis with SEMAR™ — 16

Whole Aorta CTA — 17

Lumbar Spine — 18

Right Shoulder — 20

Right Elbow — 22

Toshiba Medical gratefully acknowledges the following institution that contributed to this brochure: Klinikum Bielefeld, Germany

Reference for Radiation Dose Calculation

Calculation of the effective doses in this brochure is based on the conversion coefficients for patients given in the following publication:

American Association of Physicists in Medicine (AAPM) Report 96. "The Measurement, Reporting, and Management of Radiation Dose in CT." Report of AAPM Task Group 23 of the Diagnostic Imaging Council CT Committee. January 2008.

Brain

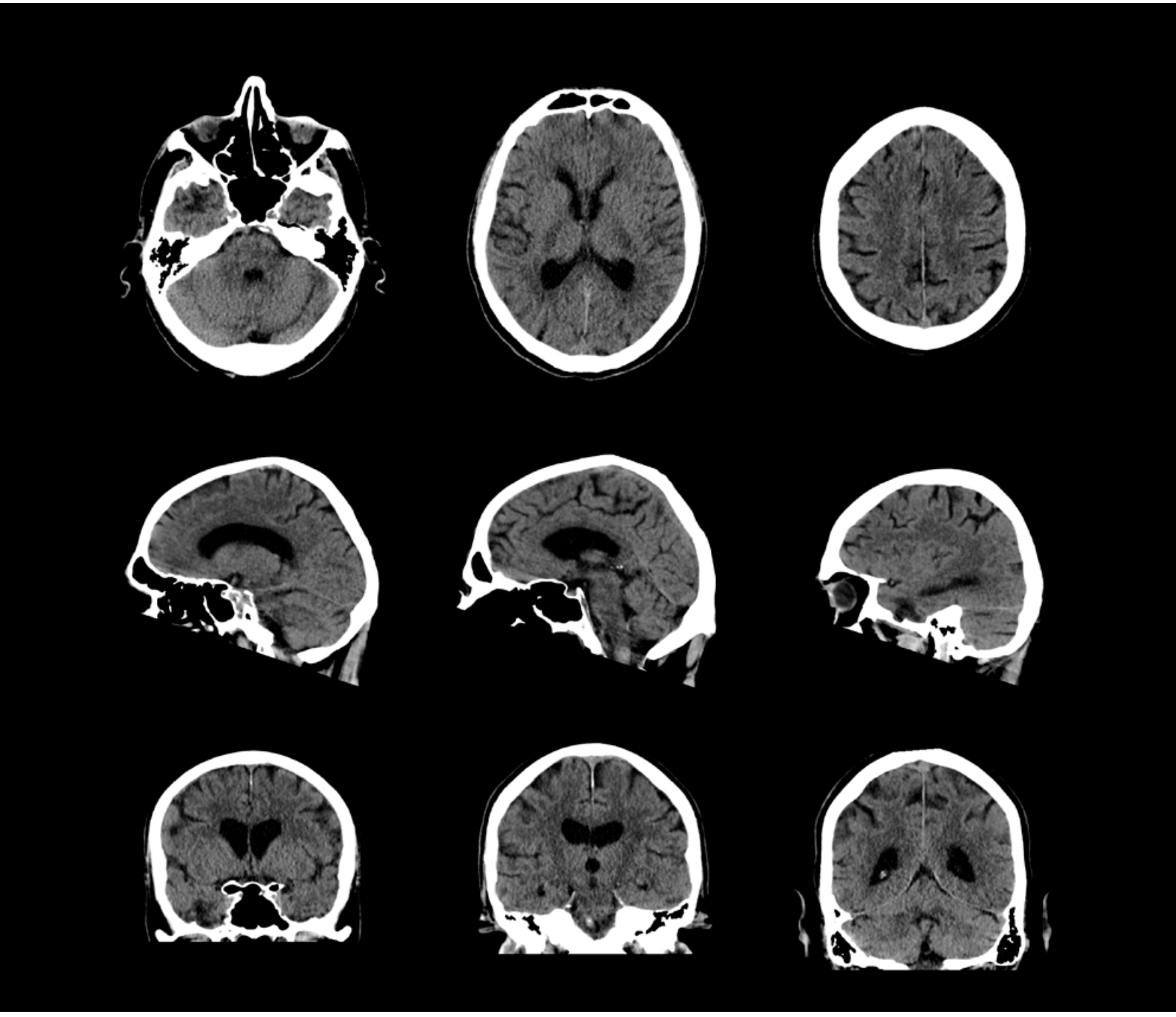

Patient History

This 68-year-old man underwent a non-contrast brain CT scan for evaluation of headaches.

Acquisition

Isotropic 0.5 mm Helical, CTDI 53.5 mGy, 1.96 mSv (k=0.0021)

Brain with Contrast

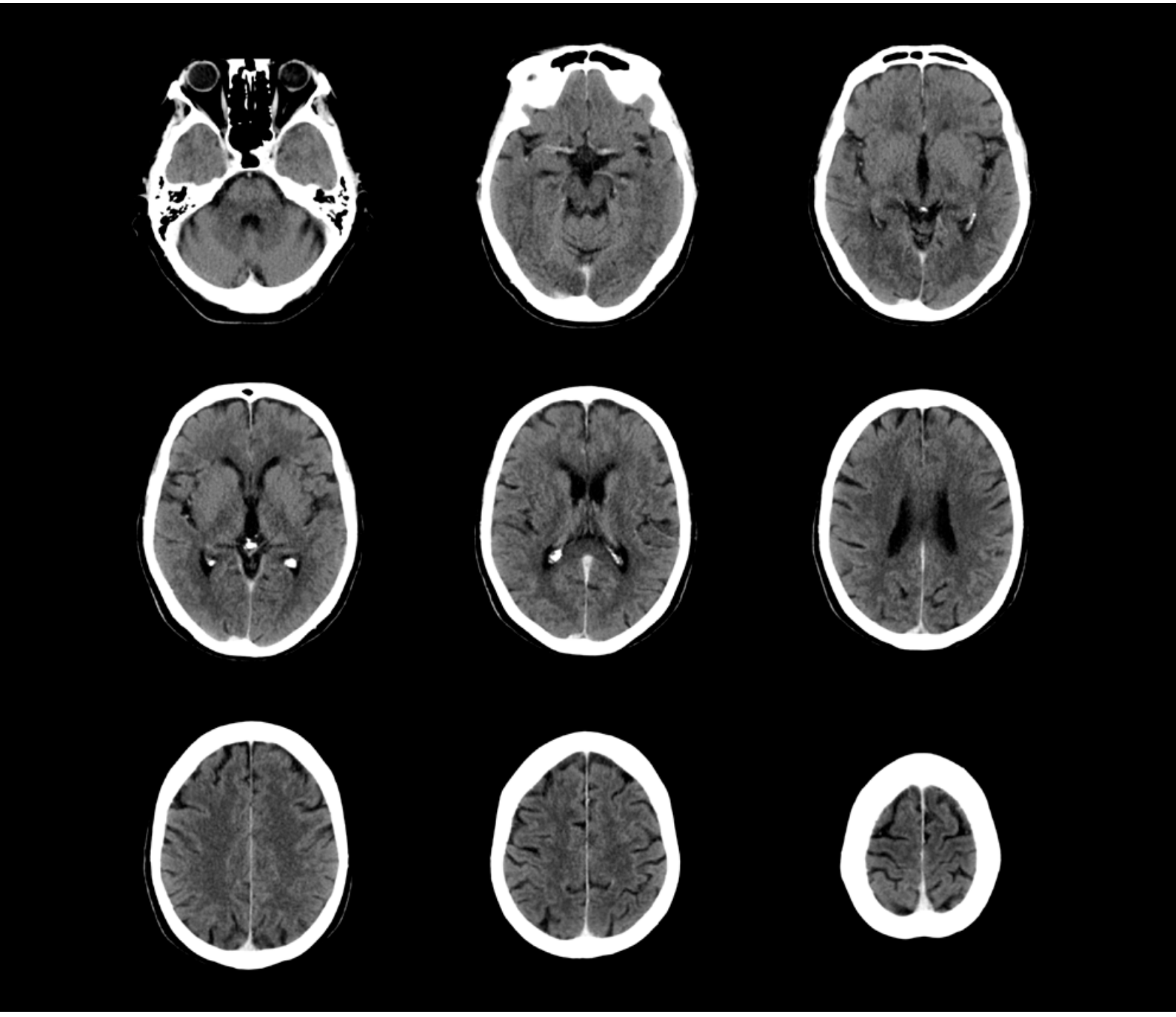

Patient History

This 67-year-old woman presented with a recent persistent headache. A CT scan of the brain was performed for evaluation of her headache.

Acquisition

80 x 0.5 Wide Volume, CTDI 52.54 mGy, 1.66 mSv (k=0.0021)

Brain and Cervical Spine

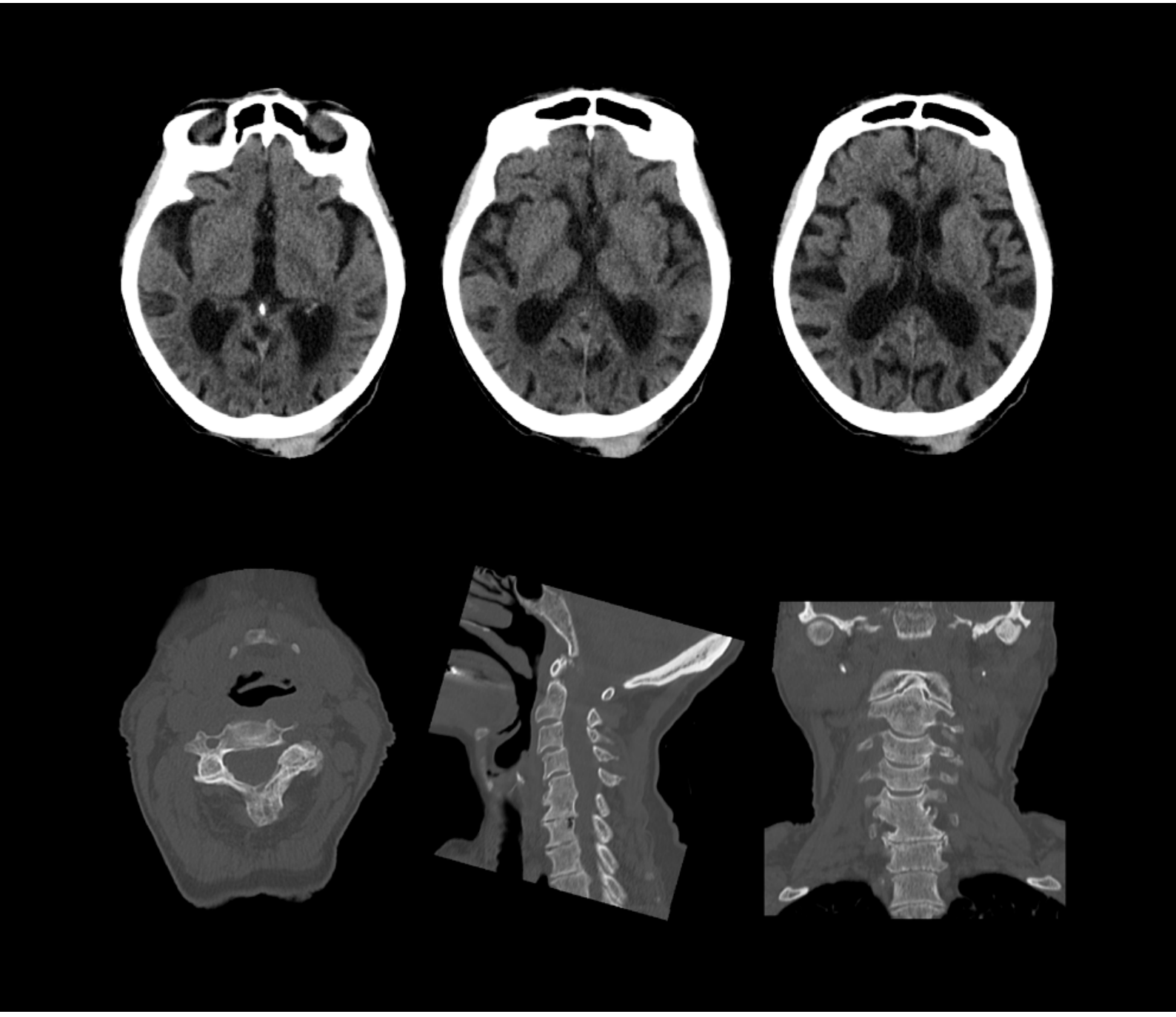

Patient History

This 88-year-old woman fell and hit her head. A CT scan of the head and cervical spine was performed to rule out bony injury or a bleed.

Acquisition

Brain Scan, CTDI 25.8 mGy, 0.92 mSv (k=0.0021)

Cervical Scan, CTDI 4.90 mGy, 0.63 mSv (k=0.0059)

Neck with Contrast

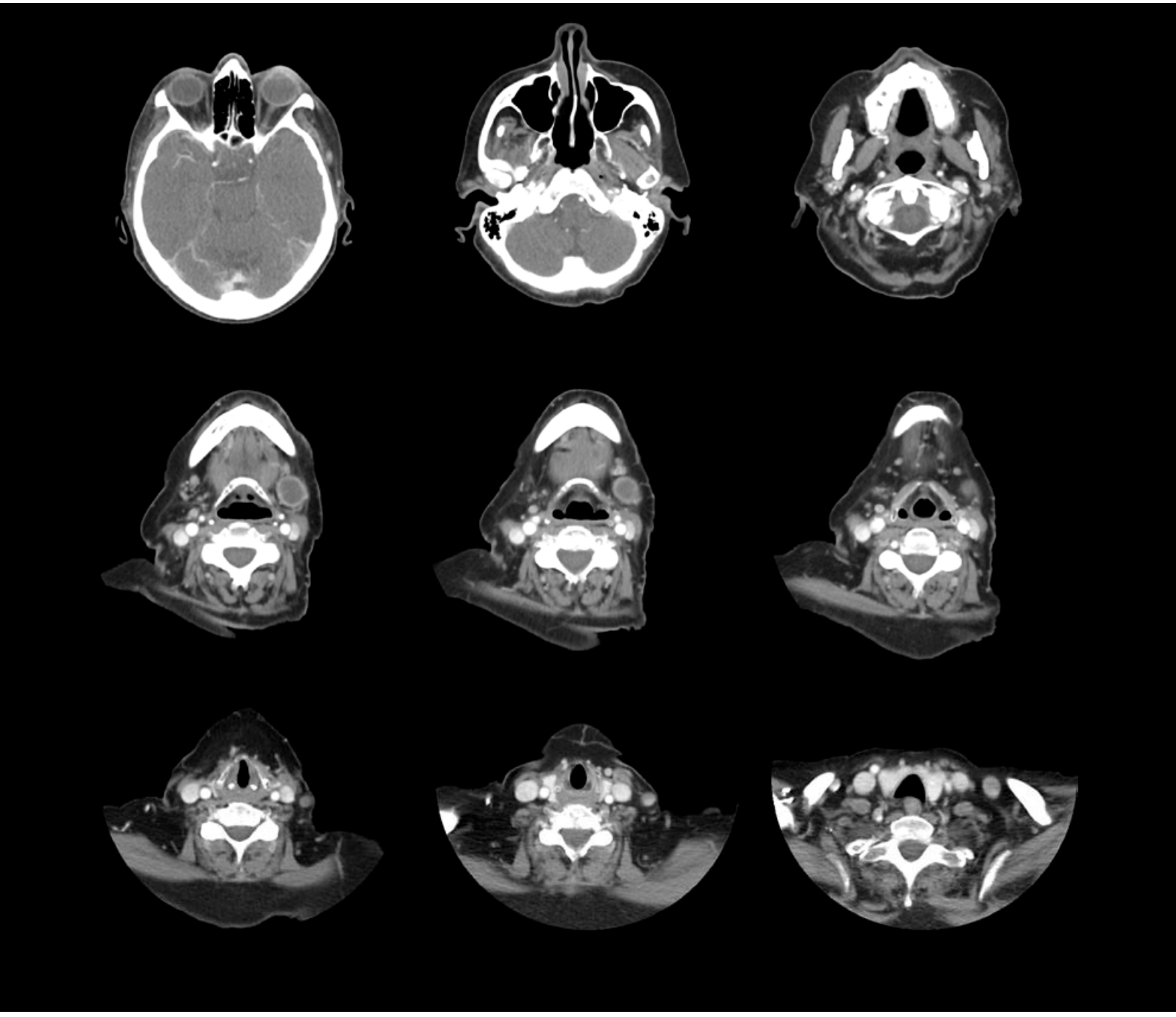

Patient History

This 77-year-old woman presented to the CT department for evaluation of a lump in the left side of her neck. A contrast CT scan of the neck was performed.

Acquisition

Ultra Helical 0.5 s rotation, CTDI 6.9 mGy, 1.23 mSv (k=0.0059)

Chest

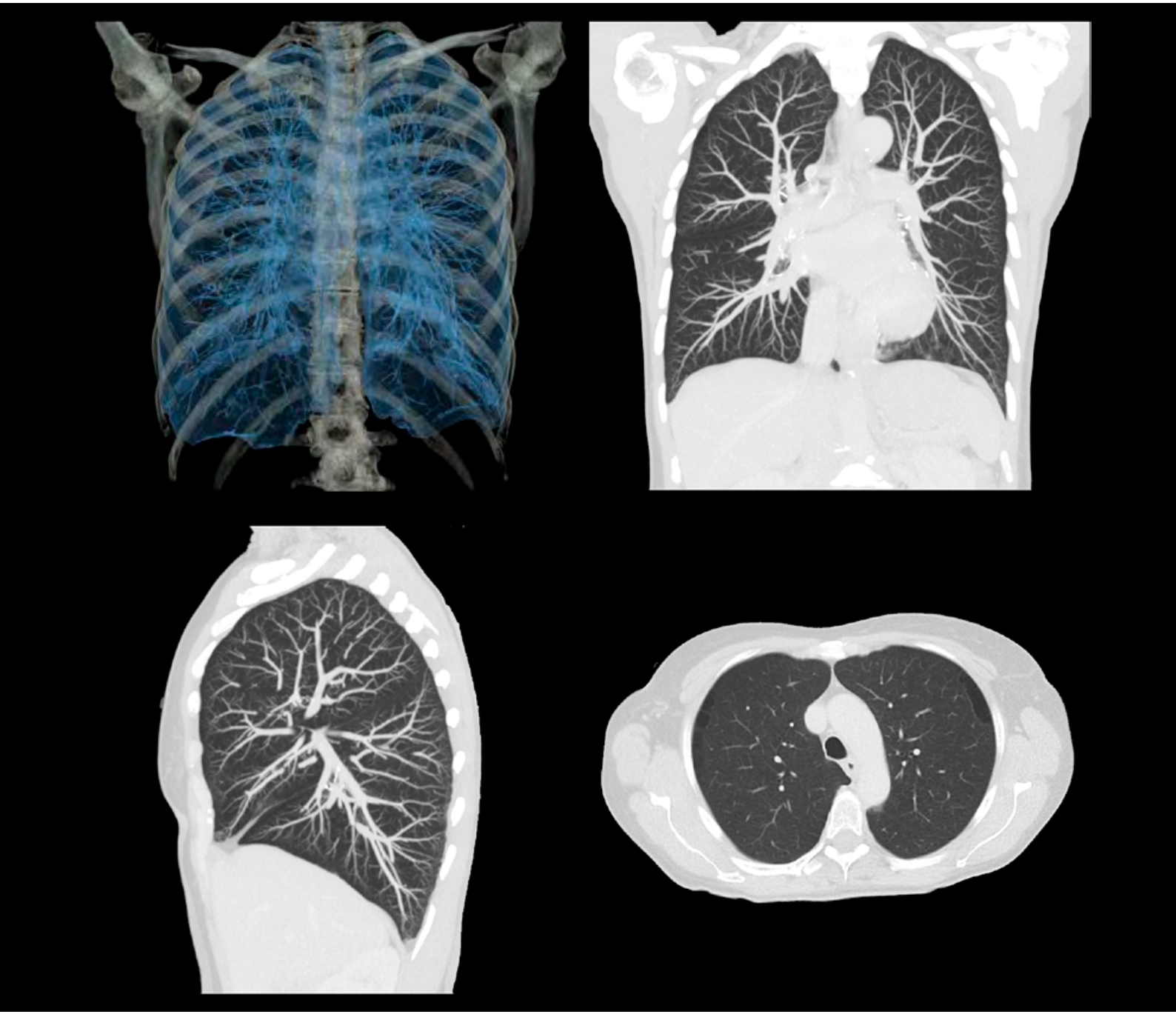

Patient History

This 43-year-old woman presented with a history of esophageal cancer. A low-dose CT of the chest was performed to rule out metastasis.

Acquisition

AIDR 3D* Scan, CTDI 2.5 mGy, 1.36 mSv (k=0.014)

* Adaptive Iterative Dose Reduction 3D

Chest Post Contrast

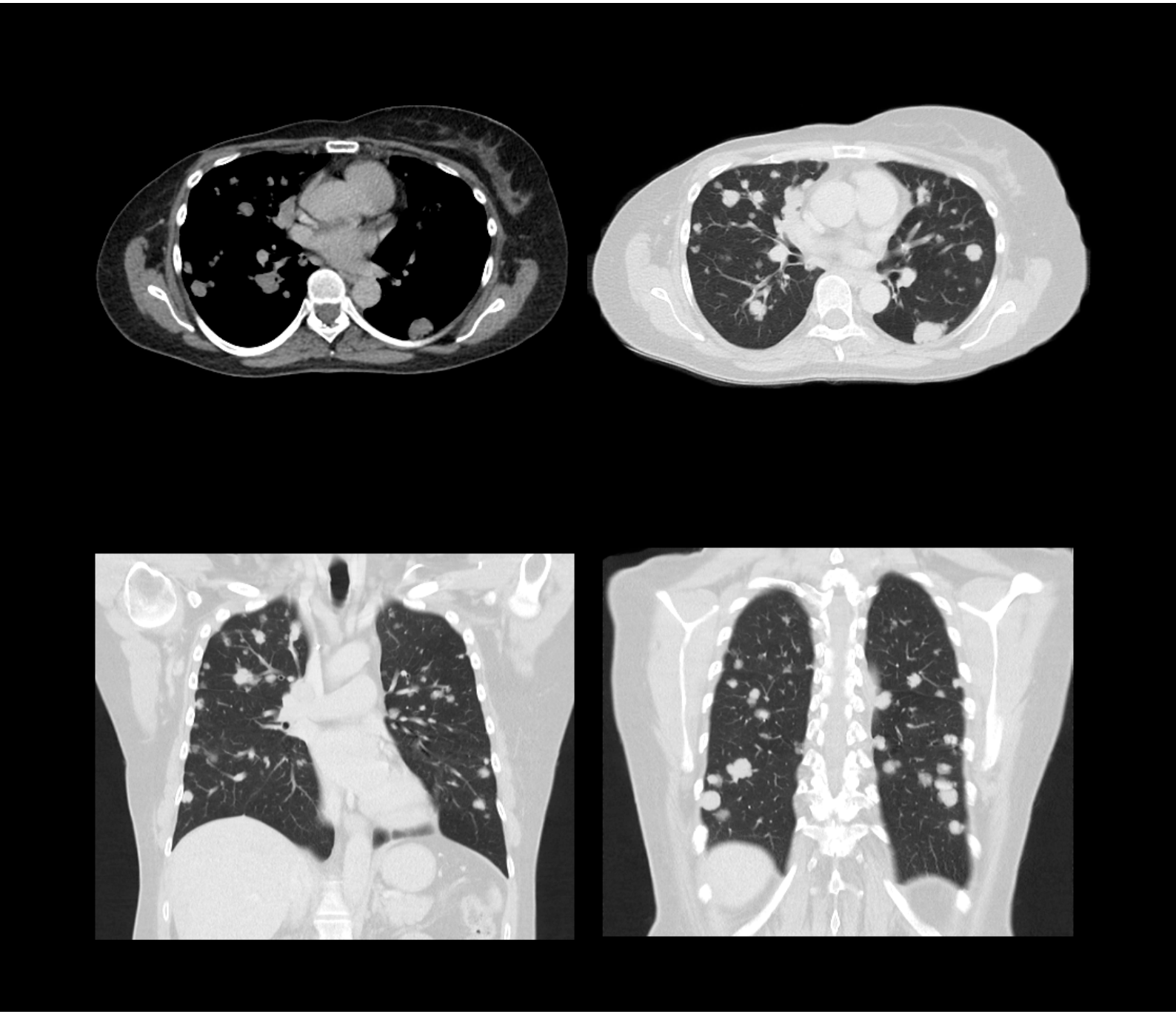

Patient History

This is a 48-year-old woman with metastatic breast cancer. A serial CT scan of the chest was performed to assess her status.

Acquisition

Ultra Helical 0.5 mm x 80, CTDI 4.6 mGy, 2.56 mSv (k=0.014)

Chest Pulmonary Angiogram

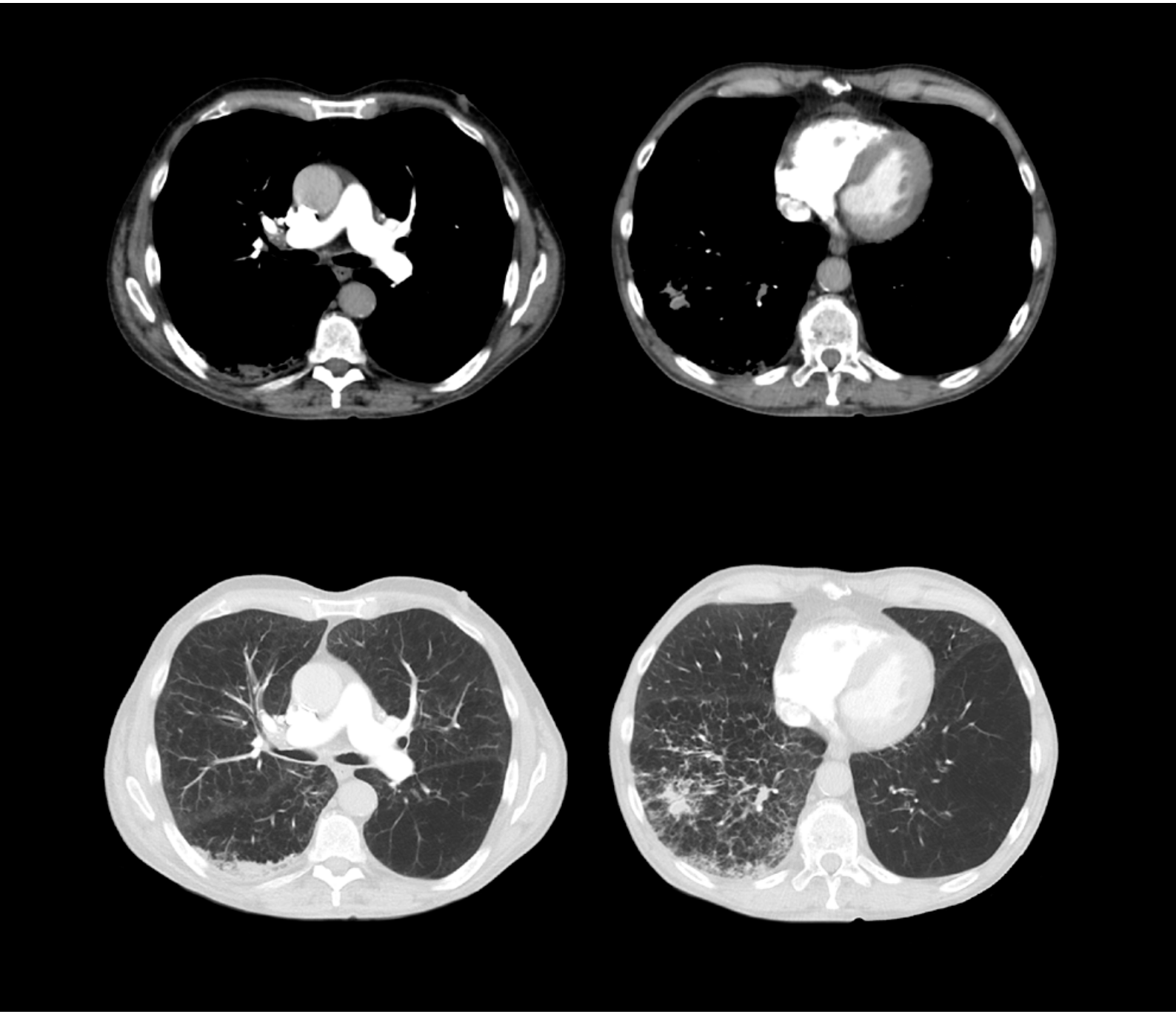

Patient History

This 72-year-old man presented with shortness of breath. A CT scan of the chest was performed to rule out pulmonary embolus.

Acquisition

SURE Start™ Bolus Timing, CTDI 5.7 mGy, 3.17 mSv (k=0.014)

Chest, Abdomen and Pelvis

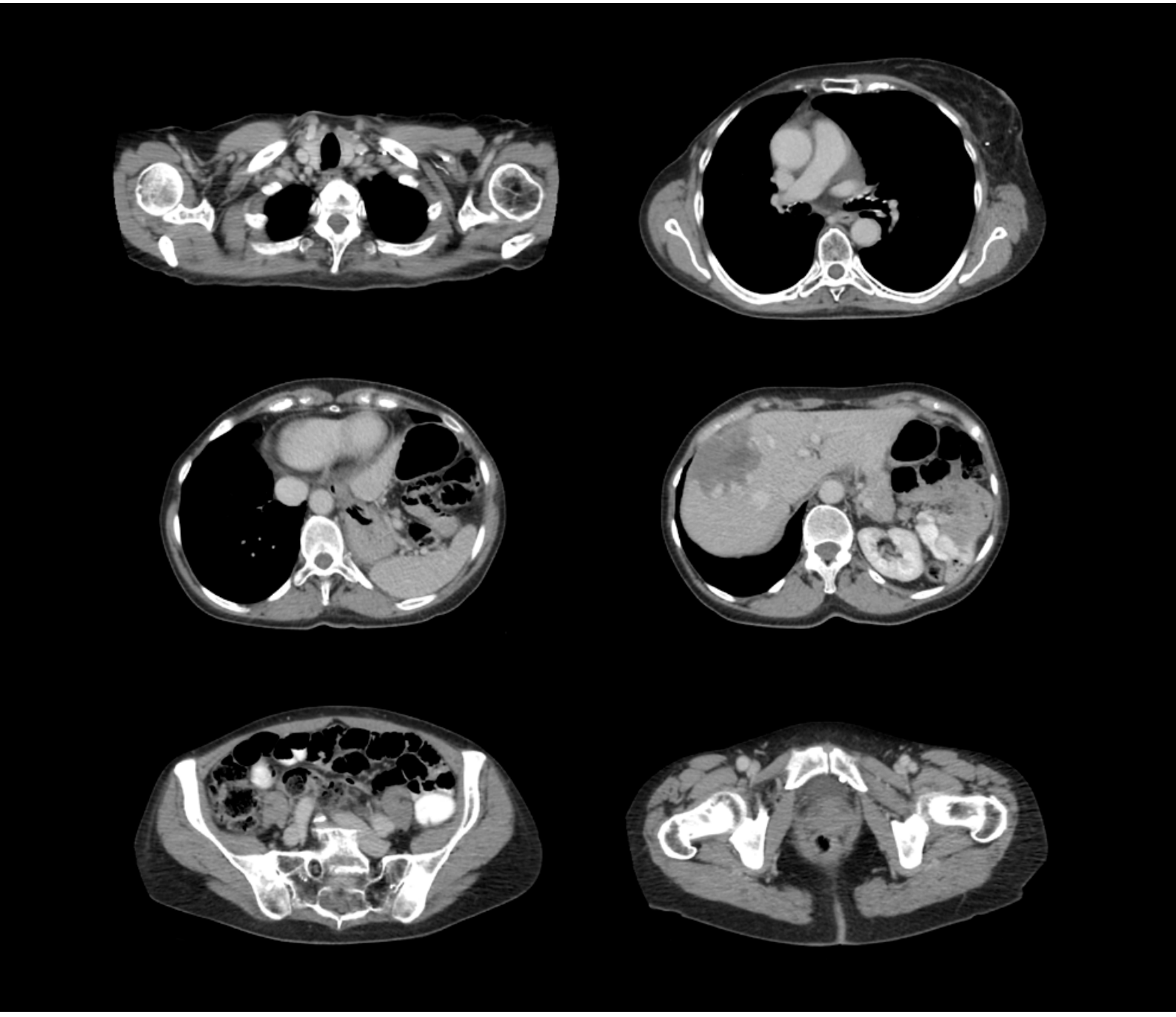

Patient History

This 65-year-old woman presented with a history of breast cancer. A CT scan of the chest, abdomen, and pelvis was performed in a serial checkup protocol.

Acquisition

Ultra Helical 0.5 mm x 80, CTDI 6.6 mGy, 6.69 mSv (k=0.0145)

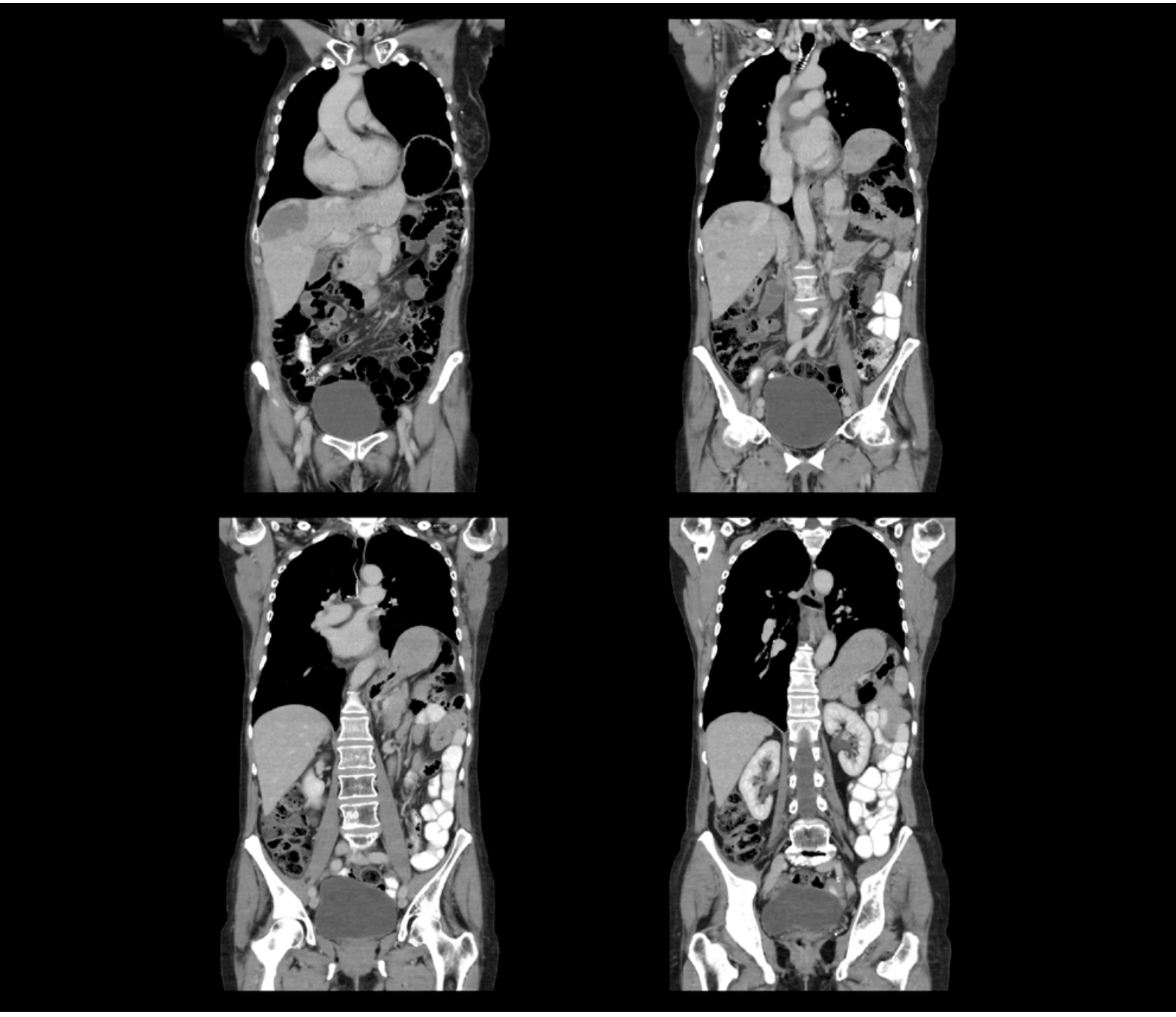

Abdomen

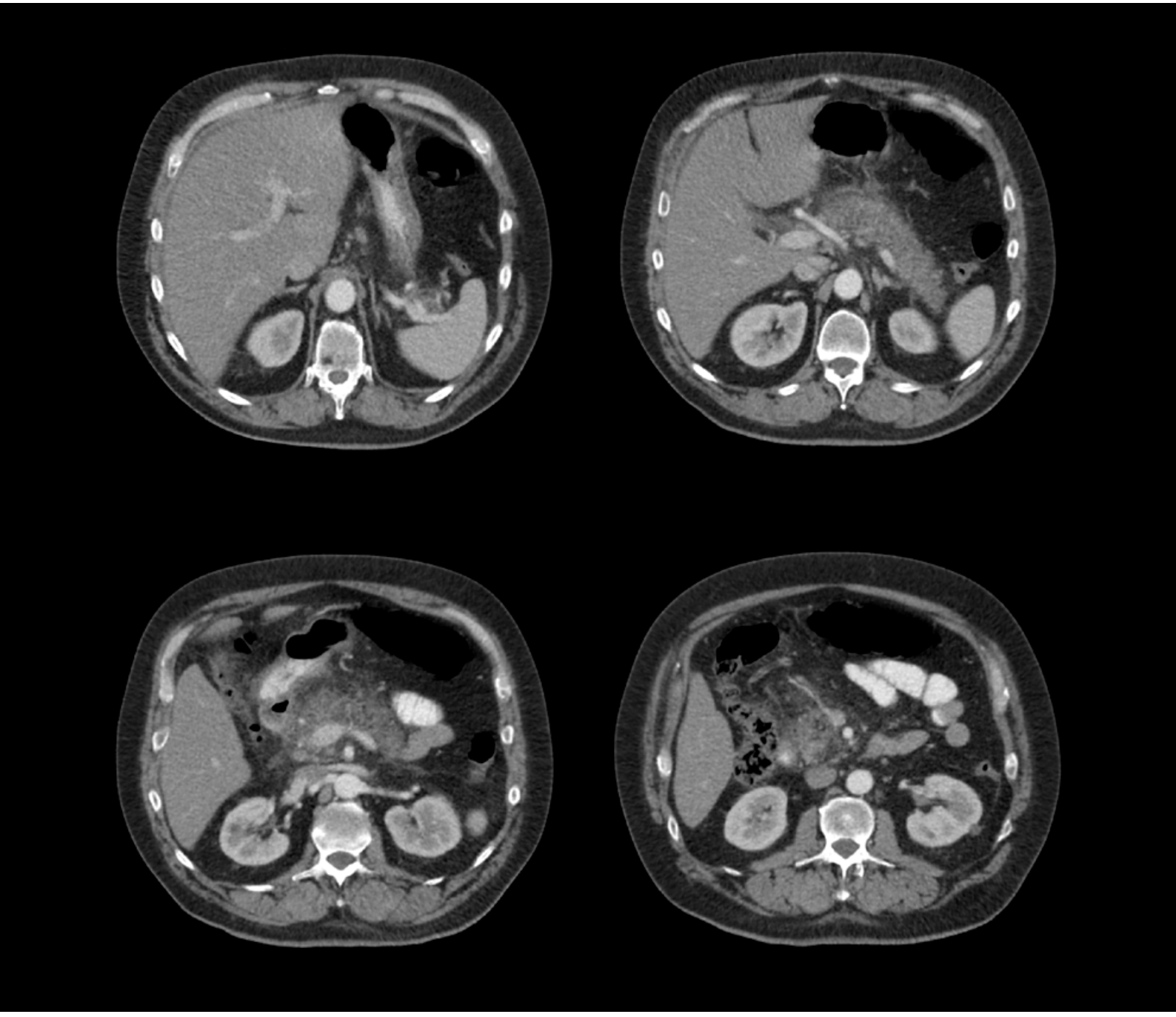

Patient History

This 54-year-old, 135 kg man presented with pancreatitis. An abdominal CT scan was performed as part of his pretreatment evaluation.

Acquisition

Arterial Phase, CTDI 17.9 mGy, 8.02 mSv (k=0.015)

Venous Phase, CTDI 17.1 mGy, 14.4 mSv (k=0.015)

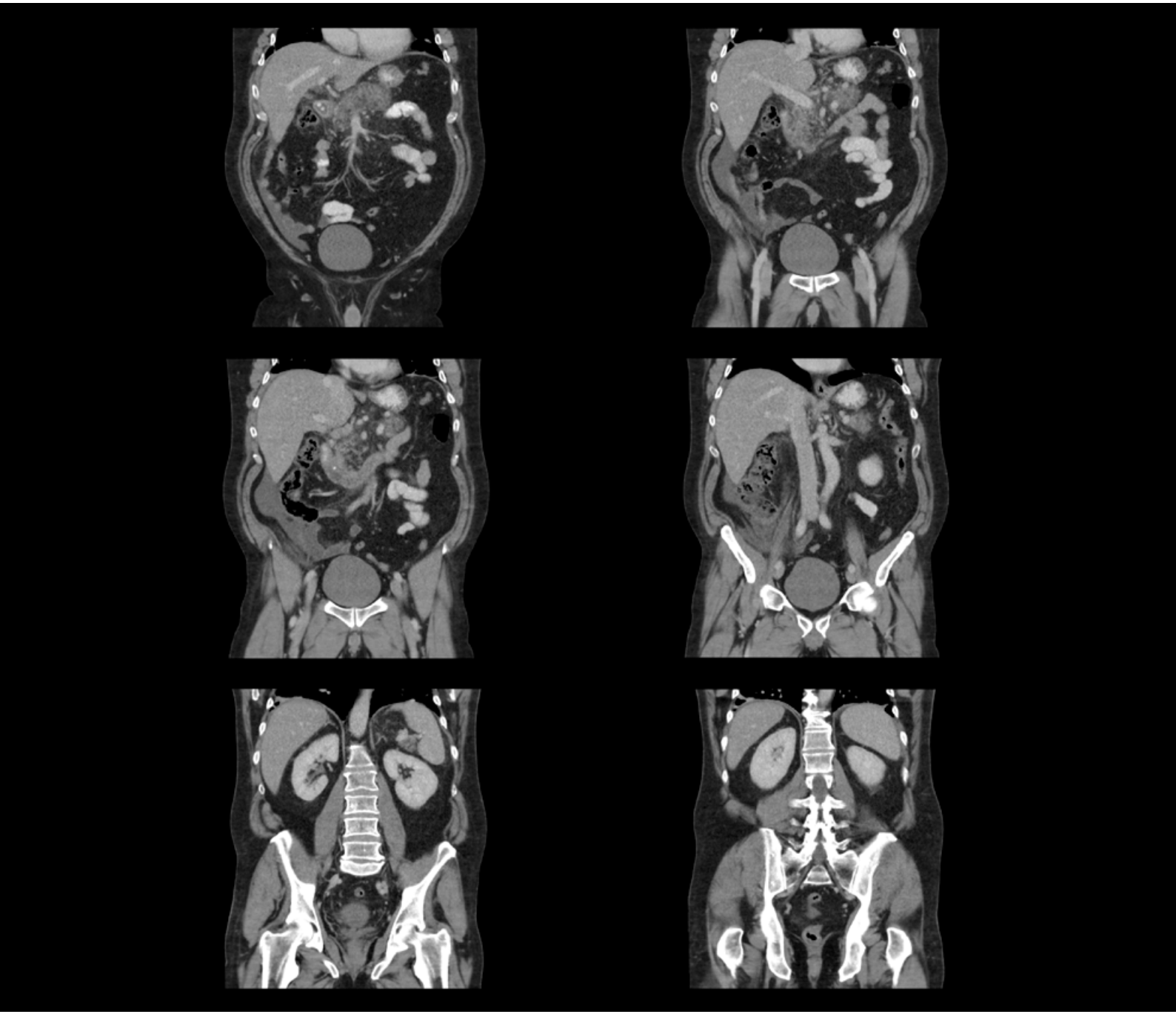

Pelvis with SEMAR*

Original

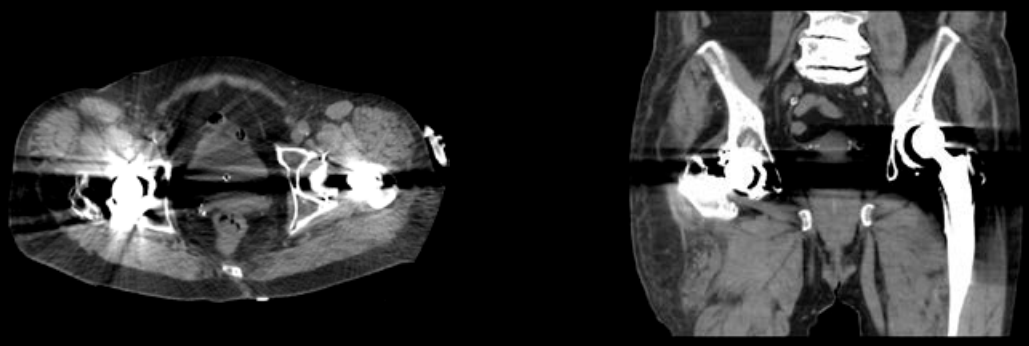

SEMAR

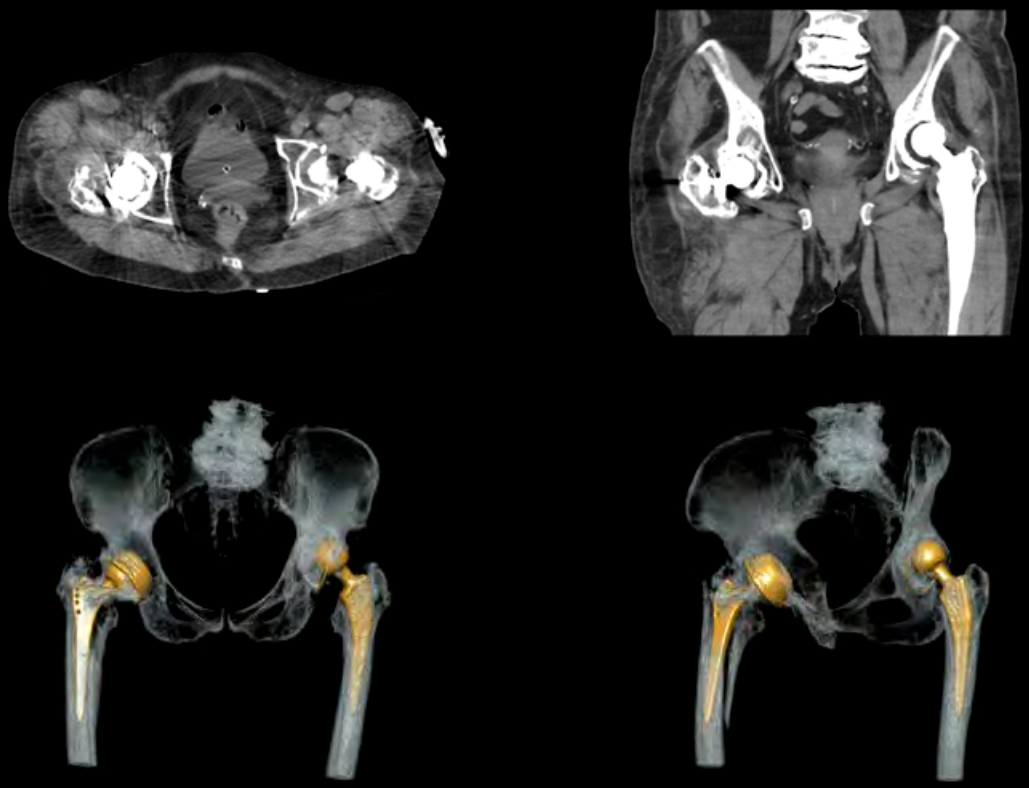

Patient History

This 80-year-old woman had undergone bilateral total hip replacement. A CT scan of the pelvis with SEMAR was performed for evaluation.

Acquisition

SEMAR Reconstruction, CTDI 8.7 mGy, 4.89 mSv (k=0.015)

* Single Energy Metal Artifact Reduction

Whole Aorta CTA

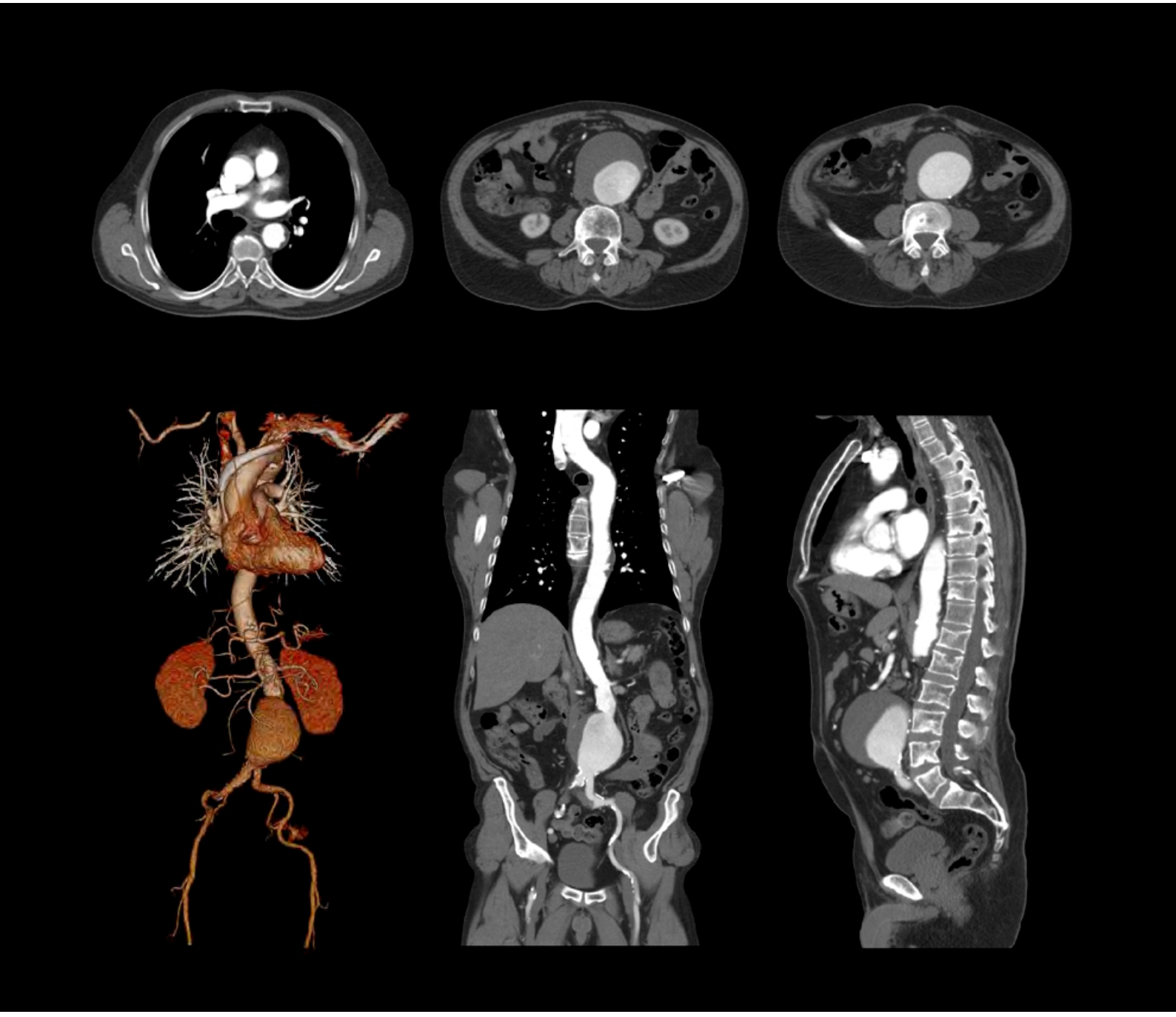

Patient History

This 64-year-old man presented to the ER with a suspected abdominal aortic aneurysm. A CT scan of the thoracic and abdominal aorta was performed.

Acquisition

SURE Start Bolus Timing, Ultra Helical 0.5 mm x 80, CTDI 8.0 mGy, 7.99 mSv (k=0.0145)

Lumbar Spine

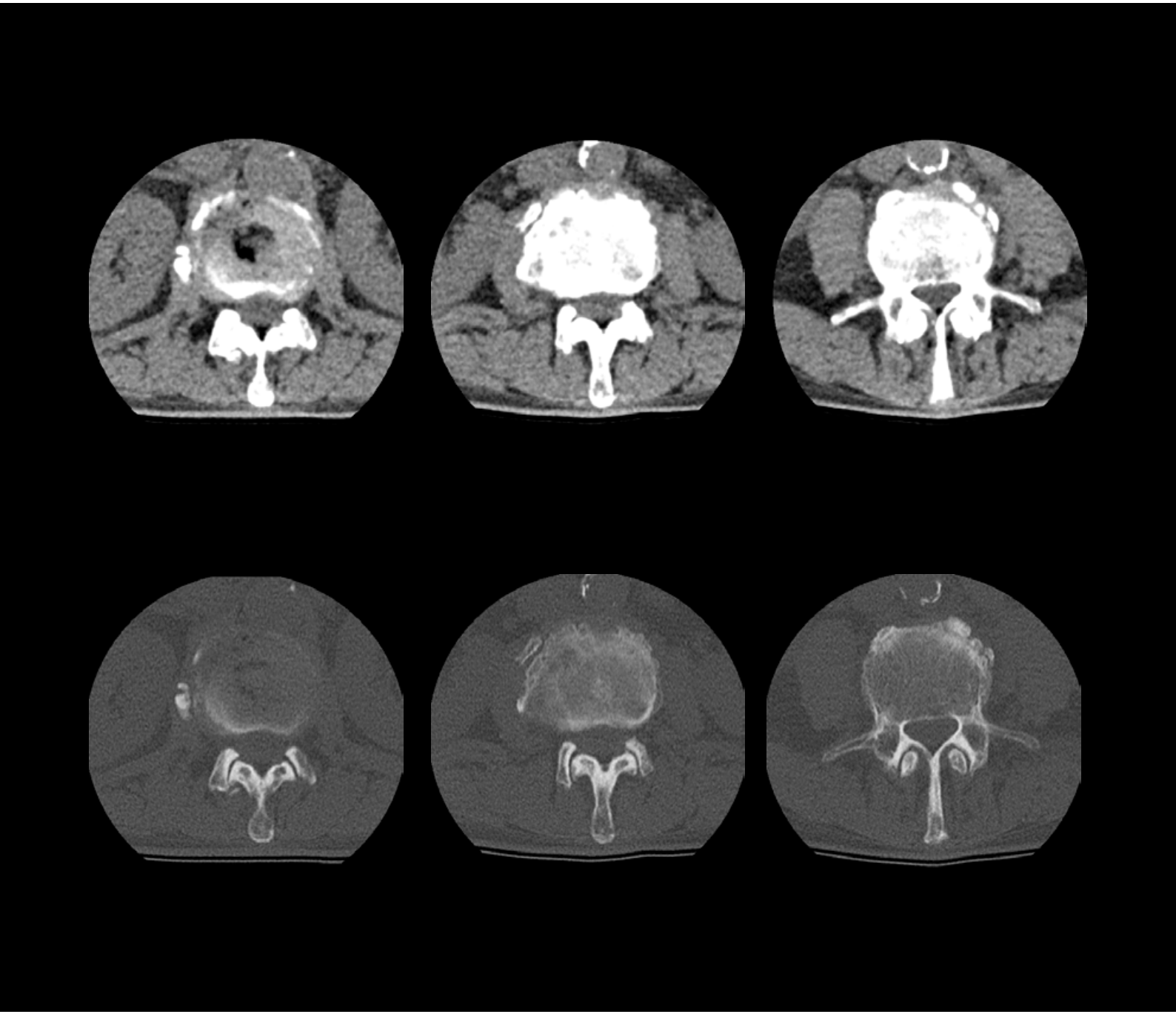

Patient History

This 68-year-old man with lower back pain could not tolerate an MRI scan due to the long scan time. However, he could tolerate a much quicker CT scan. A CT scan of the lumbar spine was performed to assess his back pain.

Acquisition

Ultra Helical AIDR 3D Scan, CTDI 4.0 mGy, 1.64 mSv (k=0.015)

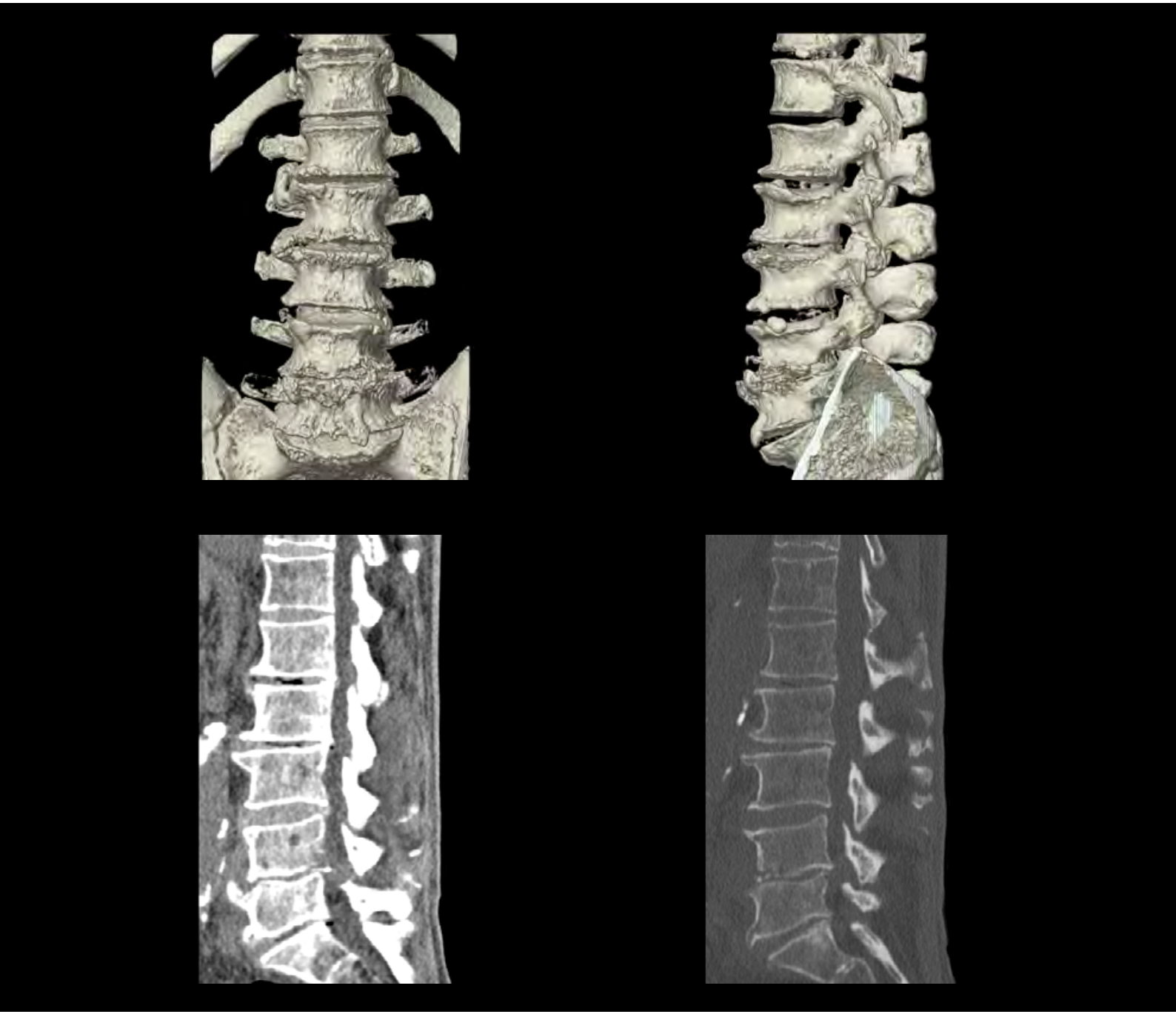

Right Shoulder

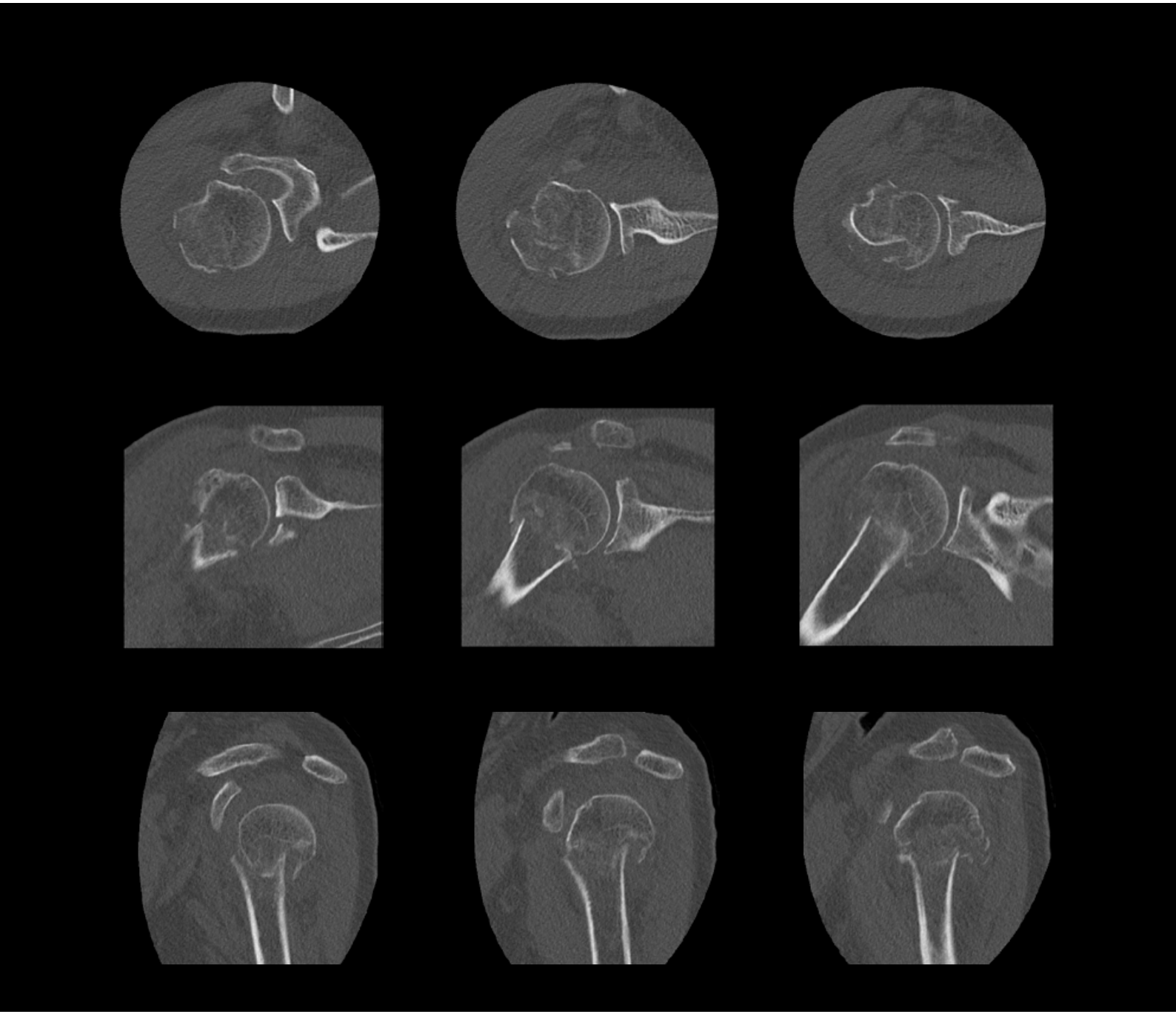

Patient History

This 82-year-old man fell onto his right shoulder. An X-ray showed a fracture of the head of the humerus. A CT scan of the right shoulder was performed to further evaluate the injury.

Acquisition

Ultra Helical 0.5 mm x 80, CTDI 14.2 mGy, 3.53 mSv (k=0.014)

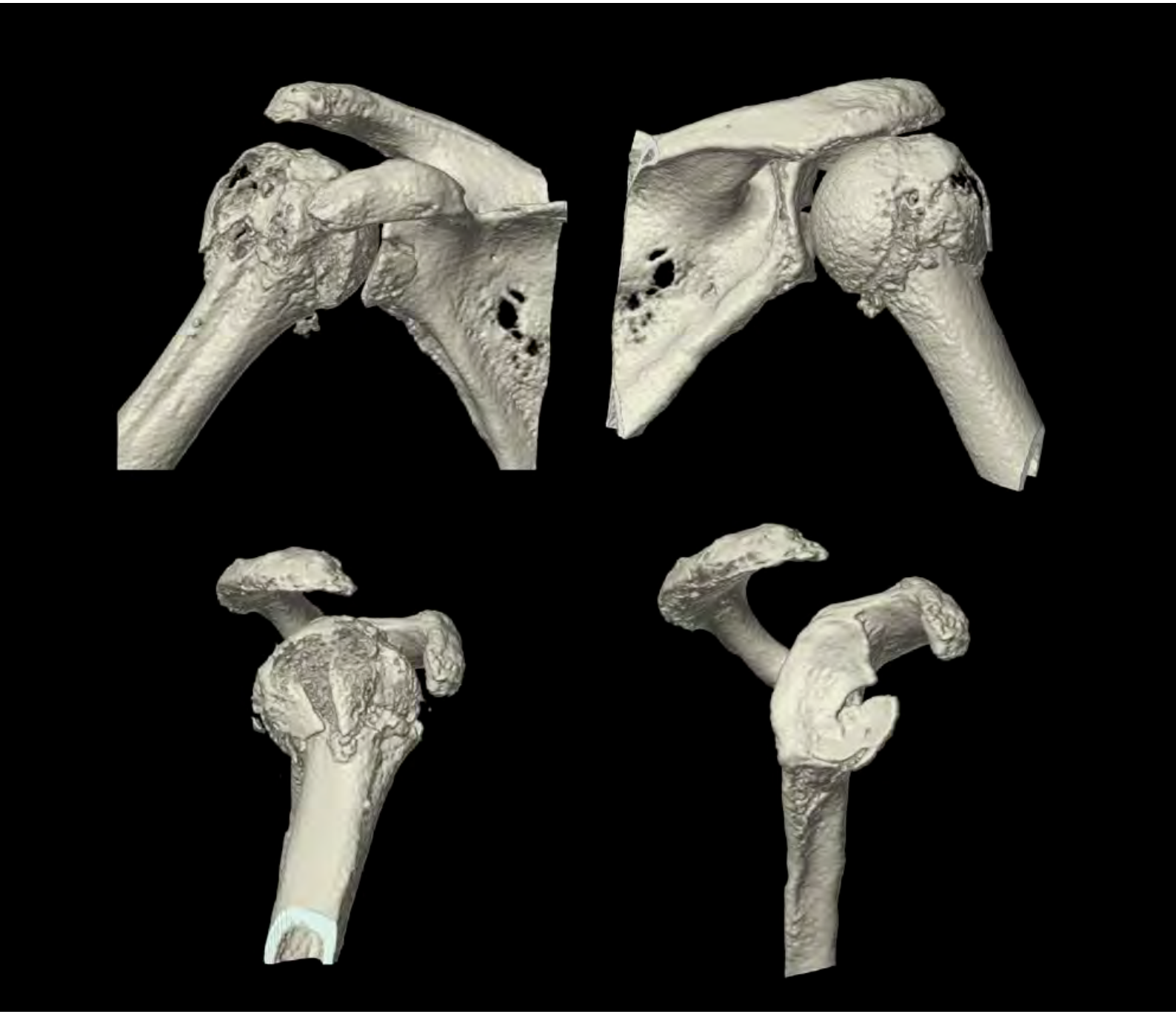

Right Elbow

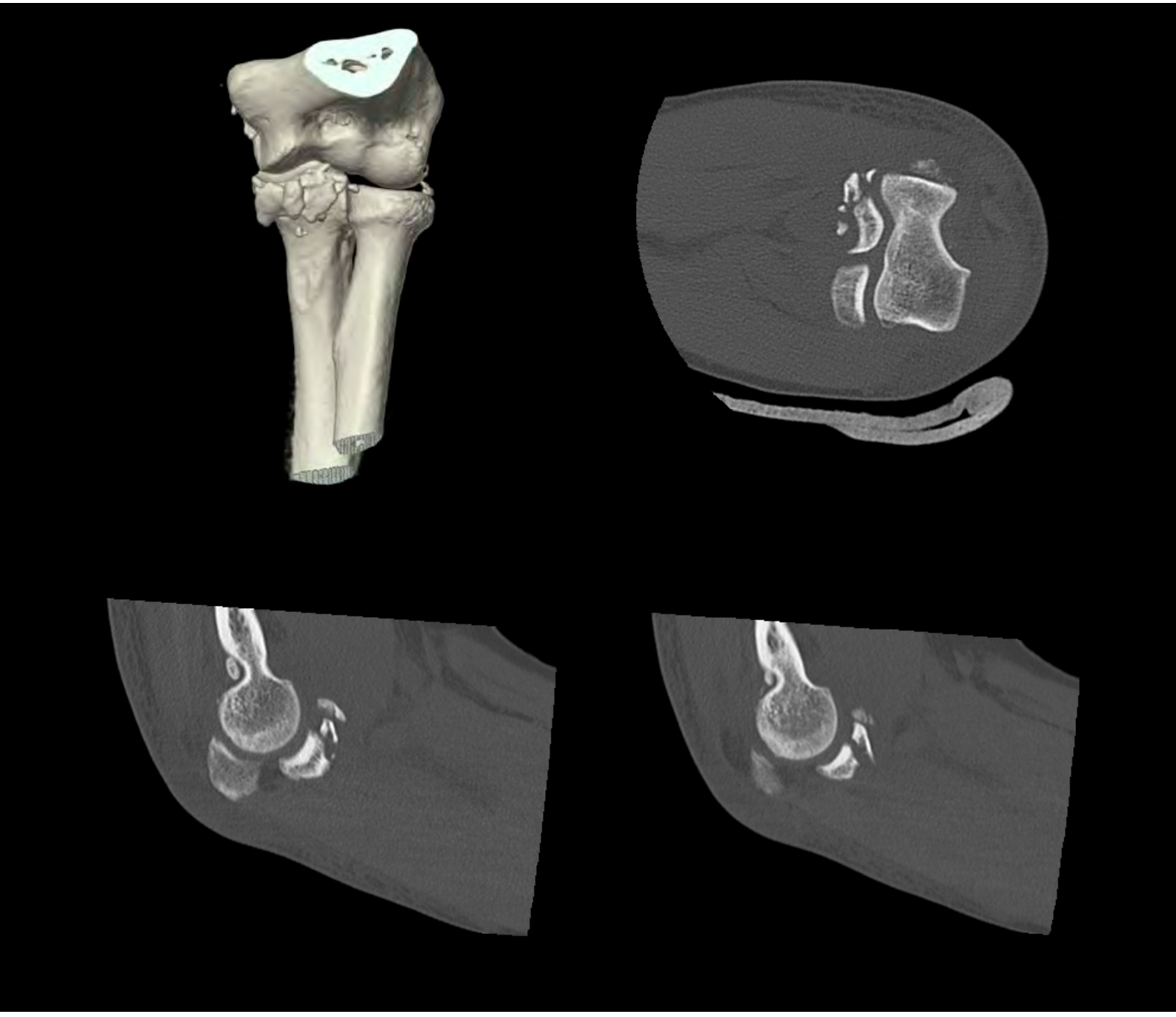

Patient History

This is a 49-year-old man presented with right elbow trauma. The elbow was immobilized with a plaster of Paris half cast. A CT scan was performed to evaluate the injury.

Acquisition

Isotropic 0.5 mm Ultra Helical, CTDI 6.4 mGy

Disclaimer: Any reference to X-ray exposure is intended as a reference guideline only. The guidelines in this document do not substitute for the judgment of a healthcare provider. Each scan requires medical judgment by the healthcare provider about exposing the patient to ionizing radiation.
In clinical practice, the use of the AIDR 3D and FIRST (Forward projected model-based Iterative Reconstruction SoluTion) features may reduce CT patient dose depending on the clinical task, patient size, anatomical location and clinical practice. A consultation with a radiologist and a physicist should be made to determine the appropriate dose to obtain diagnostic image quality for the particular clinical task.

Due to local regulatory processes, some of the products included in this brochure may not be available in each country. Please contact your sales representative for the most current information.